

CASE SERIES

Role of a topical hydrogel (Dermatix® wound care gel) in acute and chronic wound management: a case series of real-world experiences and expert opinion from Asia

Chin Yen Lee¹, Elizabeth Wei Hsi Chang², Khong Yik Chew³, Vilvkumaran Karupayah⁴, Wildan Latief⁵, Vi Anh Le⁶, Dohar Tobing⁷, Thi Phuong Thao Vu⁸, Kean Chew Wong⁹

¹Wound Care Unit, Department of Orthopaedics, Hospital Tengku Ampuan Afzan, Kuantan, Pahang, Malaysia; ²Department of Dermatology, Selayang Hospital, Selangor, Malaysia; ³Plastic, Reconstructive and Aesthetic Surgery, Singapore General Hospital, Singapore; ⁴Orthopedic and Wound Care Unit, Hospital Tengku Ampuan Rahimah Klang, Malaysia; ⁵Cipto Mangunkusumo Hospital, Jakarta, Indonesia; ⁶Department of Dermatology and Skin Aesthetics, University Medical Center of Ho Chi Minh City, Ho Chi Minh City, Vietnam; ⁷MRCCC Hospital, Jakarta, Indonesia; ⁸Hospital of Dermato-Venereology, Ho Chi Minh City, Vietnam; ⁹A. Menarini Singapore Pte Ltd., Singapore

Abstract

Moist wound healing, an established paradigm in the management of wounds, accelerates healing by maintaining an optimal microenvironment. Hydrogels, such as the Dermatix®* Wound Care (DWC) gel, possess fluid-retentive and absorptive properties and provide a moist environment for wound healing. We examined the effectiveness of DWC gel in acute and chronic wounds across various aetiologies, alone and in combination with other modalities, through a series of case studies. DWC gel promoted granulation, epithelialization, pain relief and patient adherence due to its ease of application. It is an effective and safe treatment for acute and chronic wounds; further comparative trials and research on its anti-infective and anti-inflammatory properties are warranted.

Download the **Plain Language Summary** of this article:

<https://www.drugsincontext.com/plain-language-summaries/plain-language-summary-role-of-a-topical-hydrogel-dermatix-wound-care-gel-in-acute-and-chronic-wound-management-a-case-series-of-real-world-experiences-and-expert-opinion-from-asia>

Keywords: diabetic foot ulcer, hydrogel, moist wound healing, inflammation, wound healing.

Citation

Lee CY, Chang EWH, Chew KY, Karupayah V, Latief W, Vi Le A, Tobing D, Vu TPT, Wong KC. Role of a topical hydrogel (Dermatix® wound care gel) in acute and chronic wound management: a case series of real-world experiences and expert opinion from Asia. *Drugs Context.* 2026;15:2025-8-3. <https://doi.org/10.7573/dic.2025-8-3>

Introduction

The theory of moist healing, put forward by George Winter in 1962, is now a widely accepted paradigm in wound management.¹⁻³ Compared to a dry wound environment, a moist environment accelerates the healing process through multiple mechanisms. It regulates oxygen tension at the wound site, facilitates the formation of new capillaries, enhances the breakdown of necrotic tissue and fibrin, and preserves and releases active substances within the wound exudate.⁴⁻⁷ Additionally, a

moist wound environment supports epidermal cell proliferation, differentiation and migration, maintains optimal temperature and hydration levels, and reduces the risk of infection.⁴⁻⁷

Traditional wound dressings, such as gauze, lint, plasters and bandages, were primarily designed to maintain wound cleanliness and prevent microbial contamination.^{8,9} However, these materials often adhere to the wound bed and fail to provide the moist environment conducive to optimal healing. Consequently, they have been largely supplanted by modern wound dressings,

*Registered trademark, Menarini, Singapore.

including hydrocolloids, alginates, hydrogels, foams and films, which offer improved moisture retention and reduced adherence. Given the heterogeneity of wounds in terms of location, size, depth, exudate levels, infection status and tissue adhesion, a thorough assessment of both wound characteristics and dressing properties is essential to guide the selection of the most appropriate dressing modality.^{2,10}

Hydrogels, a type of modern wound dressing, are water-based polymers that expand upon contact with water, enabling them to retain a substantial amount of water whilst preserving their structural integrity.^{11,12} This capability arises from the presence of chemically or physically cross-linked polymer chains, which form a three dimensional network.^{11,12} Given that hydrogels are composed of more than 90% water, they provide a moist wound environment conducive to tissue regeneration.^{13,14} Through chemical modifications, hydrogels can be engineered into solid, semi-solid, or liquid forms, allowing for versatile applications in wound care.¹¹ These characteristics, along with additional properties such as high porosity, responsiveness to external stimuli, soft and flexible structure, and biomimetic resemblance to living tissue, make hydrogels a highly promising material for advanced wound care applications.^{11,14,15} Furthermore, hydrogels can serve as effective carriers for antibacterial and antimicrobial agents, cells, biomolecules and growth factors, enhancing their potential for controlled drug delivery and tissue engineering applications.¹²

Dermatix (Registered trademark, Menarini, Singapore) Wound Care (DWC) gel is a paraben-free, unmedicated, acidified hydrogel that forms a semi-occlusive, breathable protective film on the wound.¹⁶ It is composed of an acidic carbomer in water stabilized by carnosine, a basic dipeptide naturally present in the skin, and a percentage of fatty substances that help reduce the evaporation of water.¹⁶ The carbomer in this 'smart' or 'intelligent' hydrogel is responsible for the principle mechanism of action of DWC gel.^{12,16} In dry wounds, it acts as a moisture-retentive barrier, inhibiting transepidermal water loss and preventing evaporation whilst hydrating the wound bed. Conversely, in exudative wounds, the carbomer exhibits fluid-absorptive properties, effectively managing excess wound exudate.¹⁶ This bifunctional activity enables the hydrogel to maintain an optimal moist wound environment across varying wound conditions.¹⁶ Additionally, the acidity of the carbomer keeps the pH of the wound low, deterring microbial growth.¹⁶

Herein, we explore the effectiveness of DWC gel in acute and chronic wounds of diverse aetiologies in patients in Asia. Through a series of case studies, we present our early experience with DWC gel, alone and in conjunction with other modalities, for the treatment of acute and chronic

wounds in centres in Singapore, Vietnam, Malaysia and Indonesia. We also provide our expert opinion, based on our practical experience, on the landscape of wound management in Asia and the role of DWC gel in wound healing.

Methods

The expert panel comprised of eight clinicians, including dermatologists ($n=3$), orthopaedic surgeons ($n=4$) and a plastic surgeon ($n=1$). The experts have extensive experience in managing different types of wounds in their routine clinical practice and represent diverse countries, healthcare settings and systems across Asia. The expert panel met in November 2024 to share their experience of using DWC gel – they presented case studies from their practice and participated in discussions on the role of DWC gel in individual cases. The case series includes 16 patients with wounds treated with DWC gel alone or in combination with other modalities. The cases included in the case series were anonymized and de-identified.

Before the meeting, the expert panel completed a survey that assessed their opinion, based on their clinical practice, on the current landscape of wound care management and the role of DWC gel in wound healing. The survey presented 19 statements for each of which the respondents chose from the following response options: 'Agree', 'Somewhat agree' or 'Disagree'; the expert panel had the opportunity to provide clarification of their choice and any further inputs. These statements and the panel's responses were further discussed at the meeting.

Case series

The cases presented at the meeting included acute ($n=9$) and chronic ($n=7$) wounds (Table 1).

Acute wounds

In acute superficial wounds with no signs of infection and little to no exudate (Cases 1 and 2), DWC gel used alone (applied two to three times a day) led to complete wound healing with minimal to no post-inflammatory hyperpigmentation and no scarring (Figures 1 and 2).

In a patient with an acute, infected ulcer secondary to a ruptured furunculosis (Case 3; Figure 3A), thrice daily application of DWC gel in conjunction with topical and oral antibiotics resulted in complete re-epithelialization of the wound in 2 weeks (Figure 3B). The patient's concern regarding the aesthetically sensitive location of the wound was addressed with easy at-home management.

A patient who presented with painful haemorrhagic ulcers on the lips, secondary to mycoplasma infection

Table 1. Summary of case studies.

	Wound type	Patient	Treatment	Outcome
Case 1 (Figure 1)	Acute superficial wound	7-year-old female patient with wound on the tip of the nose following an accident	DWC gel alone two to three times per day	<ul style="list-style-type: none"> By day 5, redness had reduced by 70% and there was no exudate By day 10 the wound had healed nearly completely without scarring
Case 2 (Figure 2)	Acute superficial wound (allergic contact dermatitis)	2-year-old female patient with wound on the foot following an insect bite	DWC gel alone two to three times per day	<ul style="list-style-type: none"> By day 3, redness and wound size had reduced by 50% and there was no more exudate By day 5, nearly complete healing with a little post-inflammation hyperpigmentation and no scarring
Case 3 (Figure 3)	Ruptured furunculosis with acute ulcer	40-year-old woman with sudden onset of painful swelling over left cheek for 5 days, which spontaneously ruptured with yellow purulent discharge; no history of insect bite or nodulocystic acne	<ul style="list-style-type: none"> Normal saline daps BD Oral antibiotics 1 week Mupirocin ointment BD DWC gel TDS Peri-wound skin care: gentle cleanser, moisturizer 	<ul style="list-style-type: none"> The wound healed with complete re-epithelialization in 2 weeks Reduced slough and purulent discharge in the wound bed was seen in 7 days, which was followed by the formation of healthy granulation tissue and healthy wound edges by 14 days
Case 4 (Figure 4)	Painful haemorrhagic ulcers secondary to mycoplasma infection	24-year-old woman with sudden-onset painful ulcers on lips and oral mucosa, which turned to painful haemorrhagic crust; no relevant history or comorbidities	<ul style="list-style-type: none"> Normal saline + antimicrobial dabs TDS Mupirocin ointment BD DWC gel QID IV acyclovir, IV azithromycin, IV analgesics Peri-wound skin care with gentle cleanser 	<ul style="list-style-type: none"> Crust on the ulcers softened gradually and was removed gently, and the ulcer/erosions underneath achieved complete re-epithelization in 1 week
Case 5 (Figure 5)	Non-healing wound after skin necrosis secondary to vascular occlusion following dermal filler	30-year-old woman with bluish discoloration and vesicles, which appeared 6 days after a dermal filler injection on the nose	<ul style="list-style-type: none"> DWC gel on crusting ulcer – 4 weeks 2 sessions of IPL 590 nm (22–25 J/cm²; 2 passes, endpoint: light grey) + fractional CO₂ (22.5 J/cm²; 5% coverage; endpoint pinpoint bleeding) + intralesional steroid injection 2 sessions of IPL 590 nm (22–25 J/cm²; 2 passes, endpoint: light grey) + fractional CO₂ (22.5 J/cm²; 5% coverage; endpoint pinpoint bleeding) Dermatix® ultra gel after 4 weeks 	<ul style="list-style-type: none"> At 4 weeks, there was a significant amount of healing DWC gel was discontinued and Dermatix® ultra gel was applied to the wound In 3 months, the wound had healed completely with hypertrophic scar

(Continued)

Table 1. (Continued)

	Wound type	Patient	Treatment	Outcome
Case 6 (Figure 6)	Hypertrophic scar and chronic, poor-healing ulcers after radioactive ³² P	58-year-old woman with several chronic poor healing wounds on left shoulder (10 years); history of radioactive ³² P use for haemangioma	<ul style="list-style-type: none"> DWC gel on the ulcer – 8 weeks 2 sessions of IPL 590 nm (22–25 J/cm²; 2 passes; endpoint: light grey) + fractional CO₂ (22.5 J/cm²; 5% coverage; endpoint: pinpoint bleeding)/ fractional picosecond laser (1064 nm; 0.4 J/cm²; 4 passes; endpoint: pinpoint bleeding) + intralesional steroid injection in the scar 2 sessions of IPL 590 nm (22–25 J/cm²; 2 passes, endpoint: light grey) + fractional CO₂ (22.5 J/cm²; 5% coverage; endpoint pinpoint bleeding) Dermatix® ultra gel after 4 weeks 	<ul style="list-style-type: none"> At 4 weeks, there was a significant healing in the ulcers At the 8-week follow-up, DWC gel was discontinued and Dermatix® ultra gel was applied to the wound In 6 months, the wound had completely healed and left a hypertrophic scar
Case 7 (Figure 7)	Healthy granulating wound following laceration	24-year-old woman with laceration injury following a motorbike accident 3 weeks previously; surgical debridement of the wound was performed, non-vital skin was excised, and the leg was put in a slab	<ul style="list-style-type: none"> DWC gel Normal saline to irrigate granulation tissue Dressing changed daily for the first 2 weeks and then every other day for 2 weeks Patient was educated on how to change dressing and made outpatient clinic visits weekly 	<ul style="list-style-type: none"> Granulation tissue decreased progressively each week following DWC gel application with complete epithelization in 5–6 weeks
Case 8 (Figure 8)	Healthy granulating wound following traumatic injury	19-year-old woman with open fracture the right tibia (Grade III) with a wound in the middle of the right lower leg; debridement with open reduction external fixation performed	<ul style="list-style-type: none"> DWC gel Normal saline to irrigate granulation tissue Dressing was changed daily for the first 2 weeks and then every other day for 2 weeks Patient was educated on how to change dressing and made outpatient clinic visits weekly 	<ul style="list-style-type: none"> Granulation tissue decreased progressively each week following DWC gel application with complete wound epithelization at the end of week 2
Case 9 (Figure 9)	Post-operative incisional wound	58-year-old woman with post-surgical wound on right elbow following surgery to correct flexion contracture of the right elbow with malunion of the right distal humerus	<ul style="list-style-type: none"> DWC gel + topical antibiotic before closing with gauze and plaster Dressing change every 3 days Peri-wound skin was closed with adhesive 	<ul style="list-style-type: none"> On day 28, the post-operative wound was significantly healed There was no exudate and no additional gap between the wound edges when it was pressed
Case 10 (Figure 10)	Post-operative wound (anterolateral thigh flap)	60-year-old woman with post-operative wound on right ankle; following surgery to remove a myxofibrosarcoma over right ankle, the patient presented with anterolateral thigh flap	<ul style="list-style-type: none"> Negative pressure wound therapy in the first 4–5 days post-surgery Topical antibiotic + DWC gel Dressing change every 3 days Peri-wound skin was closed with adhesive Local debridement 	<ul style="list-style-type: none"> At 7 weeks, the post-operative wound was significantly healed The wound was significantly narrower and there was growth of granulation tissue even above the implant

(Continued)

Table 1. (Continued)

	Wound type	Patient	Treatment	Outcome
Case 11 (Figure 11)	Diabetic foot ulcer	58-year-old woman with an infected, non-healing ulcer on left foot following a nail prick 5 months prior; patient has a history of diabetes and hypertension	<ul style="list-style-type: none"> Wound debridement DWC gel with secondary dressing polyurethane membrane for 4 weeks; dressing changed daily Shockwave therapy was added as an adjunct at the end of 3 weeks with once-weekly sessions for a further 3 weeks 	<ul style="list-style-type: none"> After debridement, the wound bed had 95% granulation tissue and 5% slough; wound size L 5.9 cm × W 3.4 cm By the end of the 3 weeks on DWC gel, the slough was reduced to 2% and there was 25% epithelialization; wound size L 4.7 cm × W 2.5 cm At the end of 7 weeks, 90% of the wound was epithelialized with 100% granulation
Case 12 (Figure 12)	Diabetic foot ulcer	68-year-old woman with non-healing wound on the left foot; patient has diabetes with neuropathy and is on oral metformin and gliclazide	<ul style="list-style-type: none"> Wound debridement DWC gel with paraffin gauze as contact layer Superoxide solution as cleansing agent Dressing change every other day 	<ul style="list-style-type: none"> In 3 months, the wound reduced in size to 1 × 1 cm with a depth of 0.5 cm Whilst the rest of the wound healed completely in 3 months, the wound over the exposed flexor tendon remained but was covered with healthy granulation tissue
Case 13 (Figure 13)	Diabetic foot ulcer	82-year-old woman with non-healing ulcer on right foot; patient has diabetes, hypertension, hyperlipidaemia, congestive cardiac failure; she was on insulin, amlodipine, losartan, simvastatin, cardiprin, bisoprolol	<ul style="list-style-type: none"> Local mechanical and sharp debridement DWC gel and contact layer with superabsorbent foam Superoxide solution/normal saline as cleansing agent Dressing change every 2 days Advised offloading 	<ul style="list-style-type: none"> In 3 months, the wound reduced in size: 1.5 × 1.5 cm, depth negligible Wound healed very well with a good moisture balance and granulation tissue
Case 14 (Figure 14)	Grade IV sacral ulcer with exposure of the sacrum	55-year-old man with a chronic non-healing ulcer in the sacral area; patient had traumatic paraplegia and has a chronic bed-bound status; he had diabetes and was on metformin; hospitalized for grade IV ulcer for 3 months	<ul style="list-style-type: none"> Wound debridement Intermittent use of negative pressure therapy with instillation for 3 months and without instillation for 3 weeks DWC gel alternating with a hydrocolloid paste for chemical debridement with silver-based non-woven dressing for 3 months 	<ul style="list-style-type: none"> After 10 months of treatment, the wound size reduced to 1 cm punctate defect with a depth of 0.5 cm

(Continued)

Table 1. (Continued)

	Wound type	Patient	Treatment	Outcome
Case 15 (Figure 15)	Venous ulcer	68-year-old man with left lower limb pain and swelling for 2 years and non-healing wound for 10 months	<ul style="list-style-type: none">• DWC gel with superabsorbent pad dressing• Daily dressing change• Compression bandage for 6 weeks followed by compression biflex thereafter• Photomodulation therapy	<ul style="list-style-type: none">• At the end of 15 weeks of treatment, only one wound remained (9.5 × 2.3 cm) with 85% epithelialization, and all other wounds healed
Case 16 (Figure 16)	Chronic non-healing vasculitic wound	71-year-old man with non-healing ulcer on right ankle	<ul style="list-style-type: none">• Conservative wound debridement• A silver-based charged fibre dressing for gentle removal of slough and retention of DWC gel, and dressing with cotton pad and tubular bandage for 3 months• Emollient cream for dry scaly peri-wound skin• Patient educated to rest the wound	<ul style="list-style-type: none">• Over 4 months, the wound size decreased by almost 50% from 18 × 10 cm to 8 × 4 cm• Wound edges became flat and flush with the wound and peri-wound redness also decreased• Objective wound improvement was seen (80% of the wound had healed) with subjective pain relief

BD, twice daily; DWC, Dermatix® Wound Care; IPL, intense pulsed light; IV, intravenous; QID, four times daily; TDS, thrice daily.

Figure 1. Resolution of acute superficial wound with minimal scarring with Dermatix® Wound Care gel used alone two to three times per day. (A) Day 1. (B) Day 10.

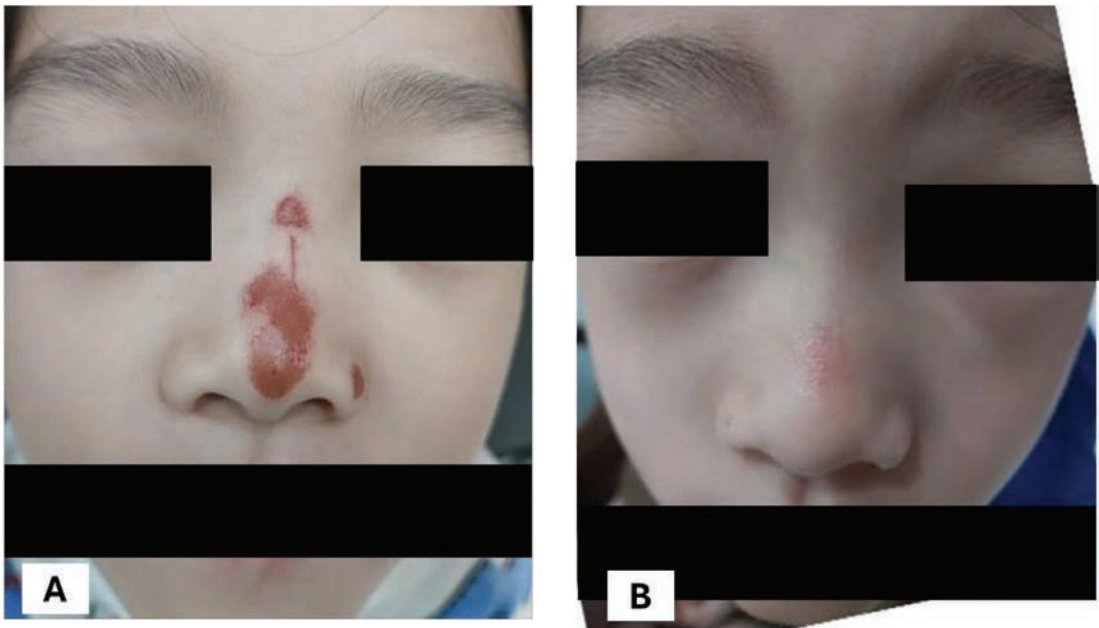


Figure 2. Resolution of acute superficial wound on the foot with minimal post-inflammatory hyperpigmentation with Dermatrix® Wound Care gel used alone two to three times/day. (A) Day 1. (B) Day 5.

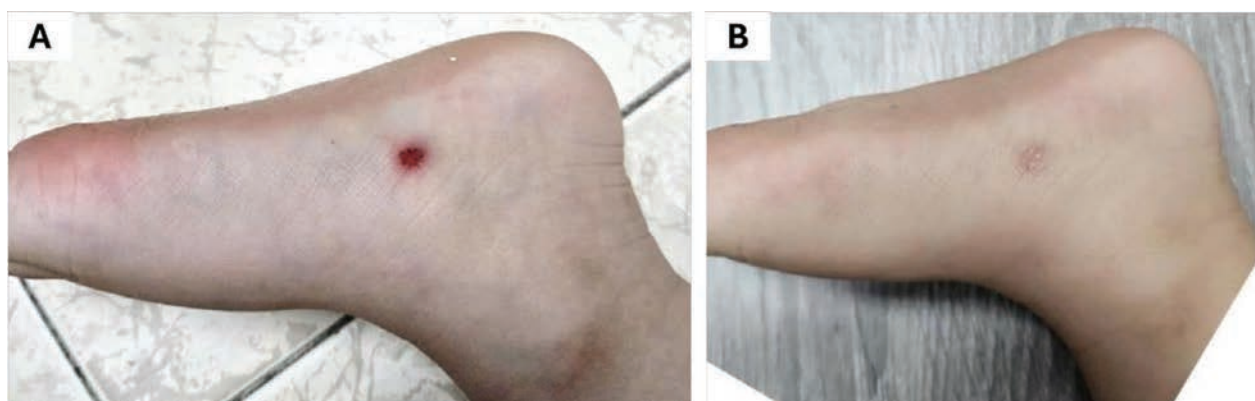
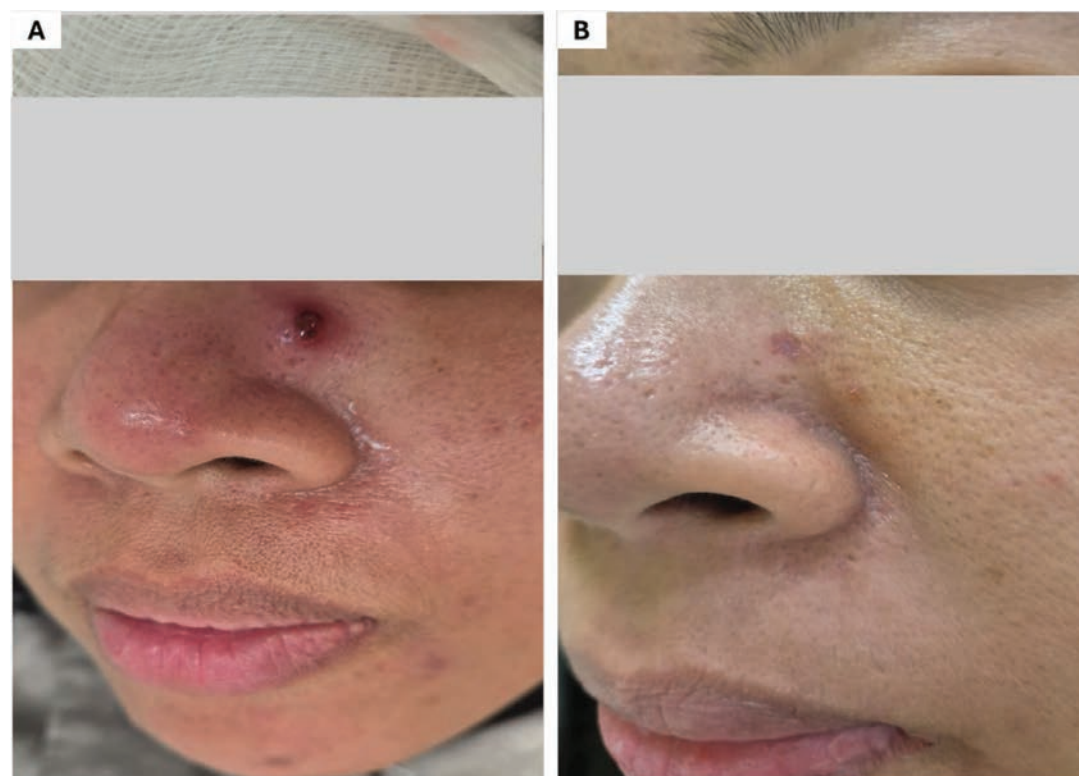


Figure 3. Complete re-epithelialization of acute ulcer secondary to ruptured furunculosis in 2 weeks following Dermatrix® Wound Care gel with topical and oral antibiotics. (A) Day 1. (B) At 2 weeks.



(Case 4; Figure 4A), required multimodal treatment to treat the pain and the infected ulcers, including topical and intravenous antibiotics, topical DWC gel, and intravenous antivirals and analgesics. At presentation, the patient was in severe pain and dysfunction due to lip ulcers; she was unable to eat or drink and found it difficult to speak. The crust on the ulcers softened with frequent

DWC gel application (four times/day) and was removed gently, and the ulcer or erosions underneath achieved complete re-epithelialization in 1 week (Figure 4B).

Poor healing wounds

Following a dermal filler injection on the nose, a patient presented with a poor-healing ulcer (3 months) on the

Figure 4. Resolution of haemorrhagic ulcers on the lips, secondary to mycoplasma infection in 1 week with topical Dermatix® Wound Care gel applied four times a day along with topical antibiotics and intravenous antibiotics, antivirals and analgesics. (A) Day 1. (B) At 1 week.

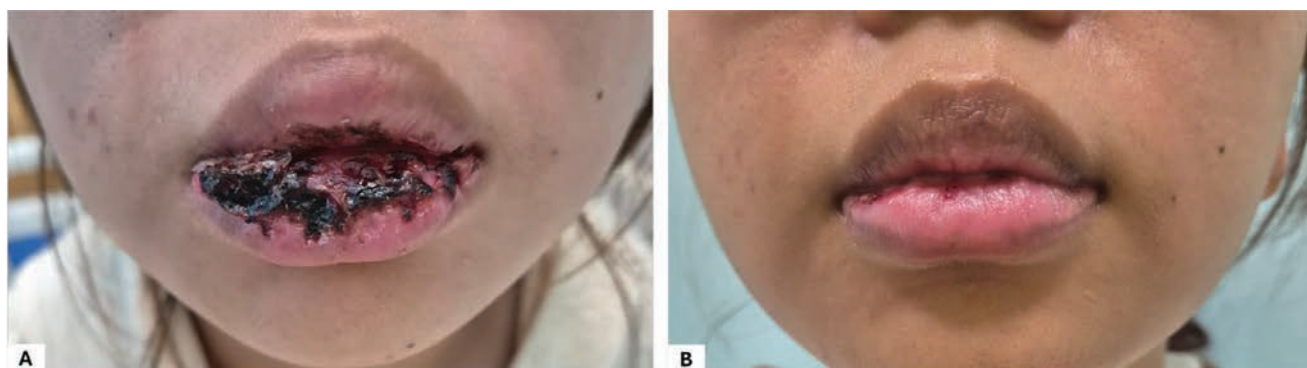
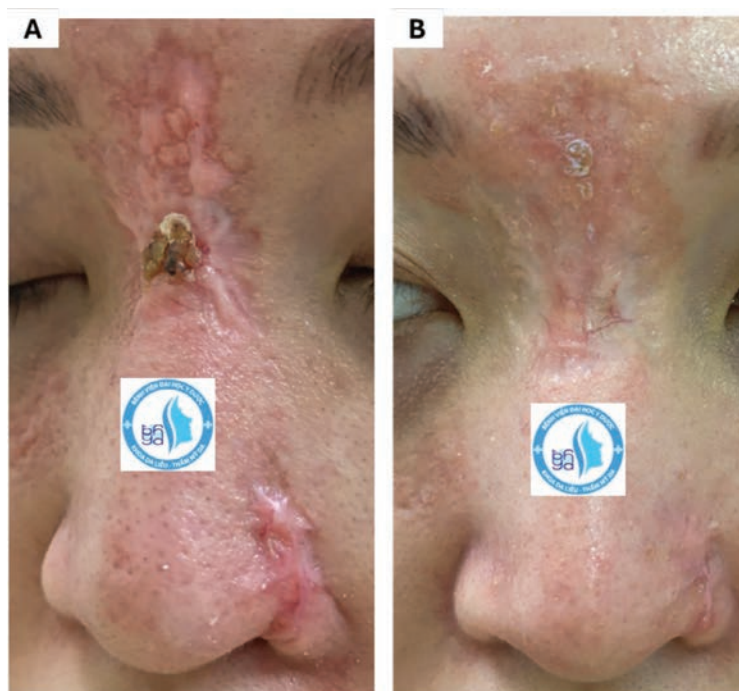


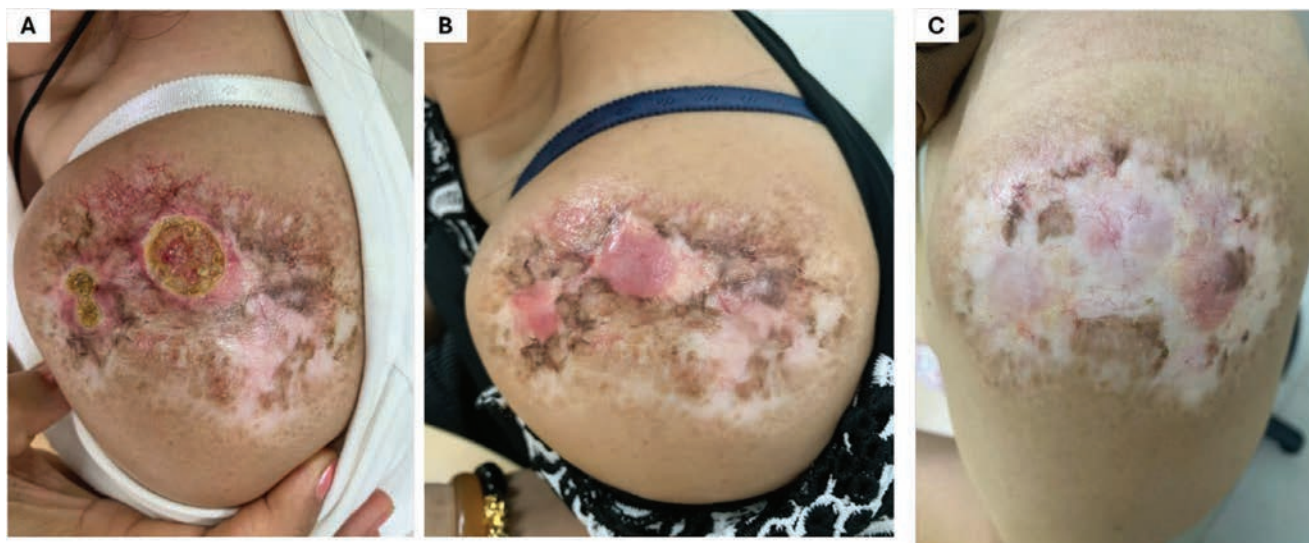
Figure 5. Complete healing of a non-healing ulcer on the radix with Dermatix® Wound Care gel, laser therapy (intense pulsed light and fractional carbon dioxide) and Dermatix® Ultra gel. (A) At presentation (3 months after dermal filler injection). (B) 3 months after the current treatment was initiated.



radix (Case 5; Figure 5A). She had received oral antibiotics for 1 week following the injection and topical mupirocin for 3 months, but the wound did not heal completely. Treatment with topical DWC gel for 4 weeks, followed by two sessions of intralesional steroid injection plus intense pulsed light (IPL) plus fractional CO₂, and two sessions of IPL plus fractional CO₂, and Dermatix Ultra gel for 3 months, led to complete wound healing with minimal post-inflammatory hyperpigmentation (Figure 5B).

A patient who was treated with radioactive Phosphorus 32 paste from 1989 to 1991 for a haemangioma on the left shoulder and continued to receive treatment in 2008, presented with poor-healing ulcers with a duration of 10 years (Case 6; Figure 6A). Topical DWC gel applied to the ulcers for 8 weeks resulted in significant healing of the wound (Figure 6B). At 8 weeks, DWC gel was discontinued, and Dermatix Ultra gel was initiated along with three sessions of IPL plus fractional CO₂ plus intralesional

Figure 6. Poor healing ulcers on the shoulder secondary to radioactive ^{32}P resolved in 6 months with remaining hypertrophic scar with Dermatrix® Wound Care gel for 8 weeks, followed by Dermatrix® Ultra gel, laser therapy (intense pulsed light and fractional carbon dioxide) and intralesional steroid injections. (A) At the current presentation. (B) At 8 weeks. (C) At 6 months.



steroid injections and six sessions of IPL plus fractional picosecond laser, which resulted in complete healing of the ulcers with a hypertrophic scar remaining at 6 months (Figure 6C).

Traumatic wounds

Traumatic wounds (Cases 7 and 8; Figures 7A and 8A) showed complete re-epithelialization and healing following surgical debridement and topical DWC gel application (Figures 7B and 8B). Topical DWC gel was applied on dry gauze to cover the wounds, which were then wrapped with elastic bandage; the dressing was changed daily for the first 2 weeks and then every other day for 2 weeks. The wound beds, which were covered with healthy granulation tissue after debridement, underwent progressive epithelialization over 4 weeks (Figures 7C and 8C).

Post-surgical wounds

A post-operative incisional wound (Case 9; Figure 9A) in a patient who underwent surgery to correct flexion contracture of the right elbow with malunion of the right distal humerus healed completely with no gap in 4 weeks with topical DWC gel used with a topical antibiotic dressing (Figure 9B).

In a patient who underwent surgery to remove a myxofibrosarcoma over the right ankle (wide excision with anterolateral thigh flap; Case 10; Figure 10A), the surgical wound healed significantly with a combination of negative pressure wound therapy during the initial 4–5 days,

and topical DWC gel and topical antibiotic dressing for 7 weeks (Figure 10B,C). The anterolateral thigh flap was thick, and the peripheral area of the flap was compromised with exposure of the tendon and surgical plate from the ankle arthrodesis anteriorly (Figure 10B). However, the wound healing progressed satisfactorily with growth of the granulation tissue even over the implant (Figure 10C).

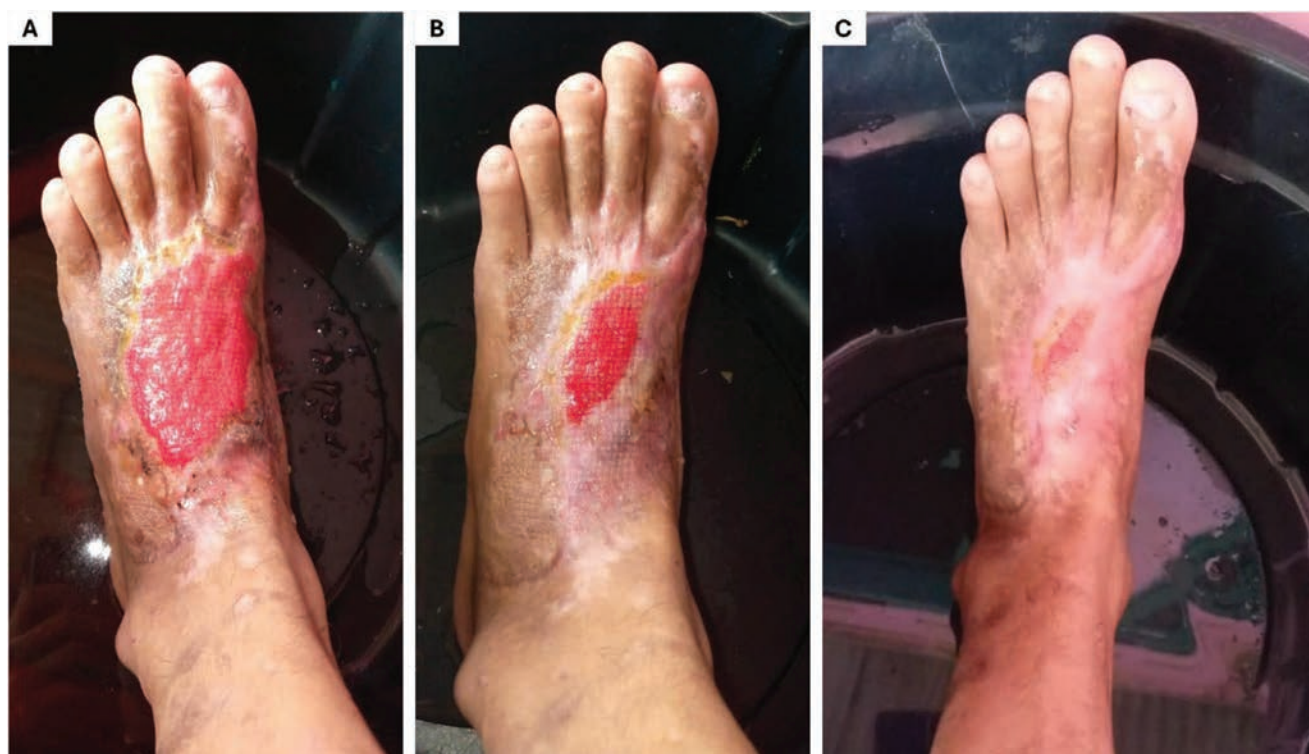Chronic wounds

Topical DWC gel was shown to promote wound healing in chronic diabetic foot ulcers (Cases 11, 12, 13), pressure ulcers (Case 14), venous ulcers (Case 15) and vasculitic ulcers (Case 16).

A 58-year-old patient with a history of diabetes and hypertension developed a foot ulcer that did not heal despite the use of multiple hydrogels along with antimicrobial and secondary foam dressings over 5 months (Case 11; Figure 11A). The ulcer showed remarkable improvement over 3 weeks following wound debridement and DWC gel applied with a secondary polyurethane membrane dressing (Figure 11B). At the end of 3 weeks, shockwave therapy was introduced as an adjunct with once-weekly sessions for 3 weeks. By 7 weeks, the wound had healed with >90% epithelialization (Figure 11C). The patient was satisfied with DWC gel because it was simple and convenient to use.

A non-healing ulcer (>2 months duration) on the plantar aspect of the left forefoot in a patient with a history of diabetes (Case 12) improved with granulation

Figure 7. Improvement in laceration wound on the dorsum of the foot following surgical debridement and application of Dermatrix® Wound Care (DWC) gel* for 4 weeks. (A) Immediately following surgical debridement. (B) At 4 weeks of DWC gel application. (C) At 5–6 weeks of DWC gel application.



*DWC gel was applied on dry gauze to cover the wound, which was then wrapped in elastic bandage daily; dressing changed daily for the first 2 weeks and then every other day for 2 weeks.

and epithelization in 3 months with DWC gel dressing (changed every other day) after wound debridement (Figure 12A–C). Given the location of the ulcer, off-loading was recommended, but the patient was non-compliant. Although a part of the wound over the flexor tendon of the big toe remained exposed at the end of 3 months, it was covered with healthy granulation tissue. The patient was satisfied with the progress of wound healing.

In an 82-year-old woman with multiple comorbidities, including diabetes, a foot ulcer on the medial plantar aspect of the right foot initially managed with debridement followed by daily dressing at home or primary care clinic did not lead to any improvement in the wound. Local mechanical and sharp debridement followed by application of DWC gel and contact layer with superabsorbent foam (dressing changed every 2 days) resulted in significant wound improvement over 3 months (Case 13; Figure 13). Wound healing was sped up with the assistance of DWC gel as well as patient education and diabetes control.

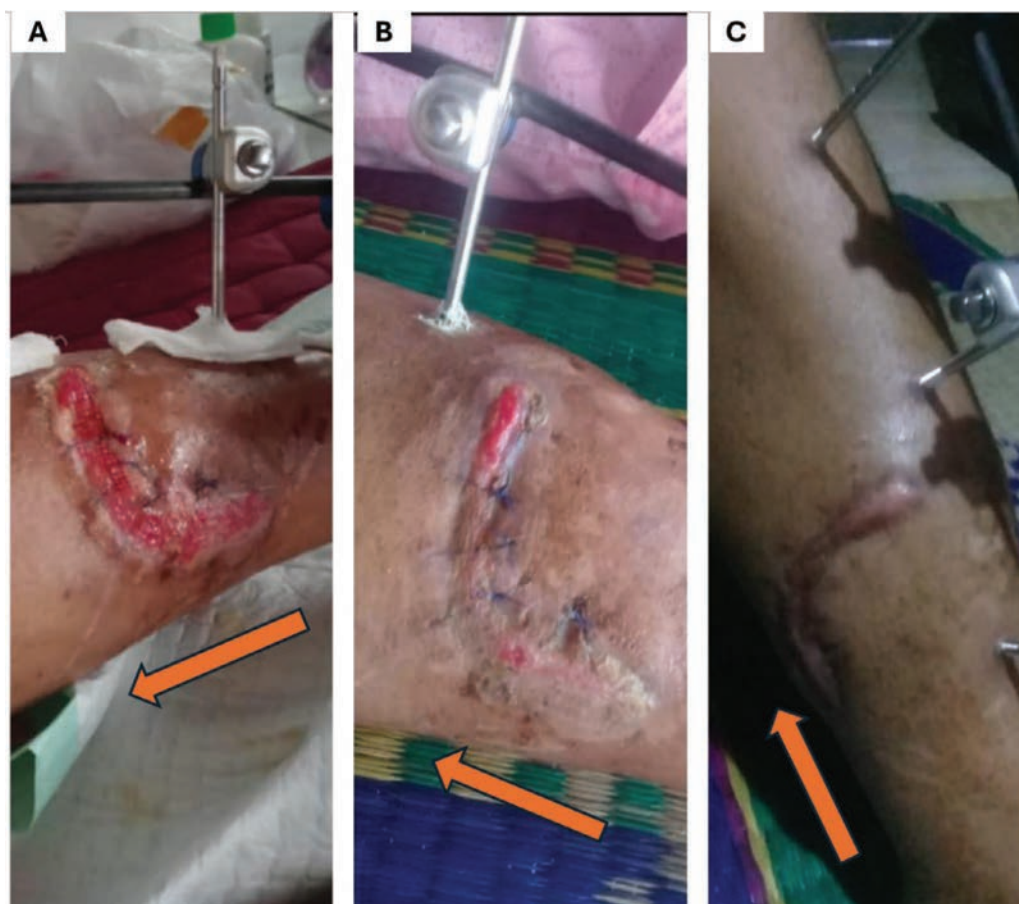
An infected pressure ulcer in the sacral area (Case 14; Figure 14A) of a bed-bound patient with paraplegia and

diabetes was initially managed with debridement followed by intermittent use of negative pressure therapy with wound instillation for 3 months and without instillation for a further 3 weeks, leading to resolution of the infection and improvement in the wound (Figure 14B,C). Thereafter, application of DWC gel alternating with a hydrocolloid paste for chemical debridement and silver-based non-woven dressing for 3 months led to a marked reduction in the wound size with a remnant punctate ulcer (Figure 14D).

In a patient with a history of hypertension and previous venous ulcers (Case 15), who presented with four non-healing (>10 months) and heavily exudative venous ulcers of varying sizes on the left lower leg, application of DWC gel with superabsorbent pad dressing or polyurethane membrane as secondary dressing and compression bandage for 15 weeks led to complete epithelialization of all but one ulcer, which was also markedly reduced in size and 85% epithelialized (Figure 15A–F).

A chronic non-healing ulcer (>2 years) on the right ankle of a patient with polycythaemia vera and autoimmune vasculitis on treatment with hydroxyquinone and

Figure 8. Improvement in traumatic wound on the lower right leg following surgical debridement and application of Dermatrix® Wound Care (DWC) gel* for 4 weeks. (A) 1 week following wound debridement with open reduction external fixation. (B) After 2 weeks. (C) After 4 weeks (arrows indicate the position of the head).



*DWC gel applied on dry gauze to cover the wound, which was then wrapped in elastic bandage daily; dressing changed daily for the first 2 weeks and then every other day for 2 weeks.

Figure 9. Post-surgical incisional wound healed with no gaping with topical Dermatrix® Wound Care gel with a topical antibiotic dressing (changed every 3 days) for 4 weeks. (A) Immediately following surgery. (B) At week 4.

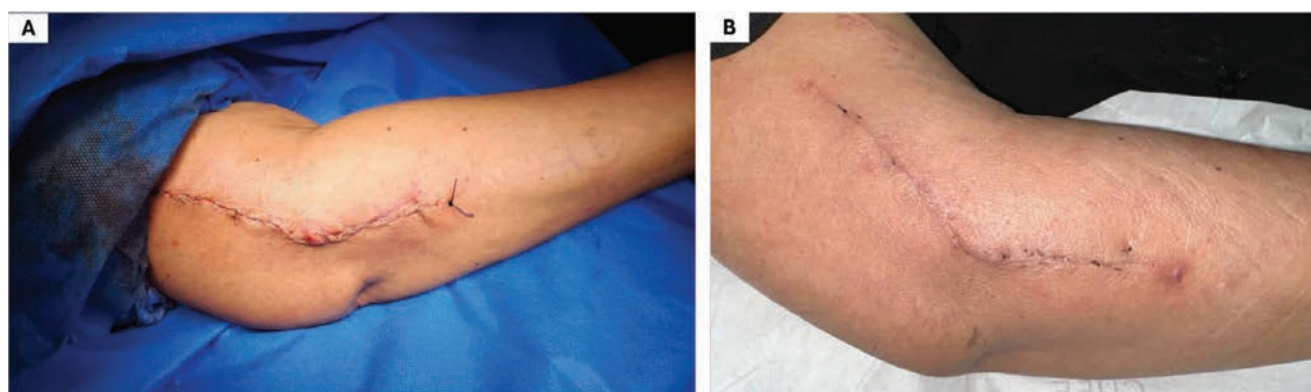


Figure 10. Wound healing in a post-operative wound (wide excision to remove a myxofibrosarcoma with anterolateral thigh flap) with negative pressure therapy for 4–5 days post-operatively and, topical Dermatrix® Wound Care gel and topical antibiotic dressing for 7 weeks. (A) Immediately post-surgery. (B) 2 weeks post-surgery. (C) 7 weeks post-surgery.

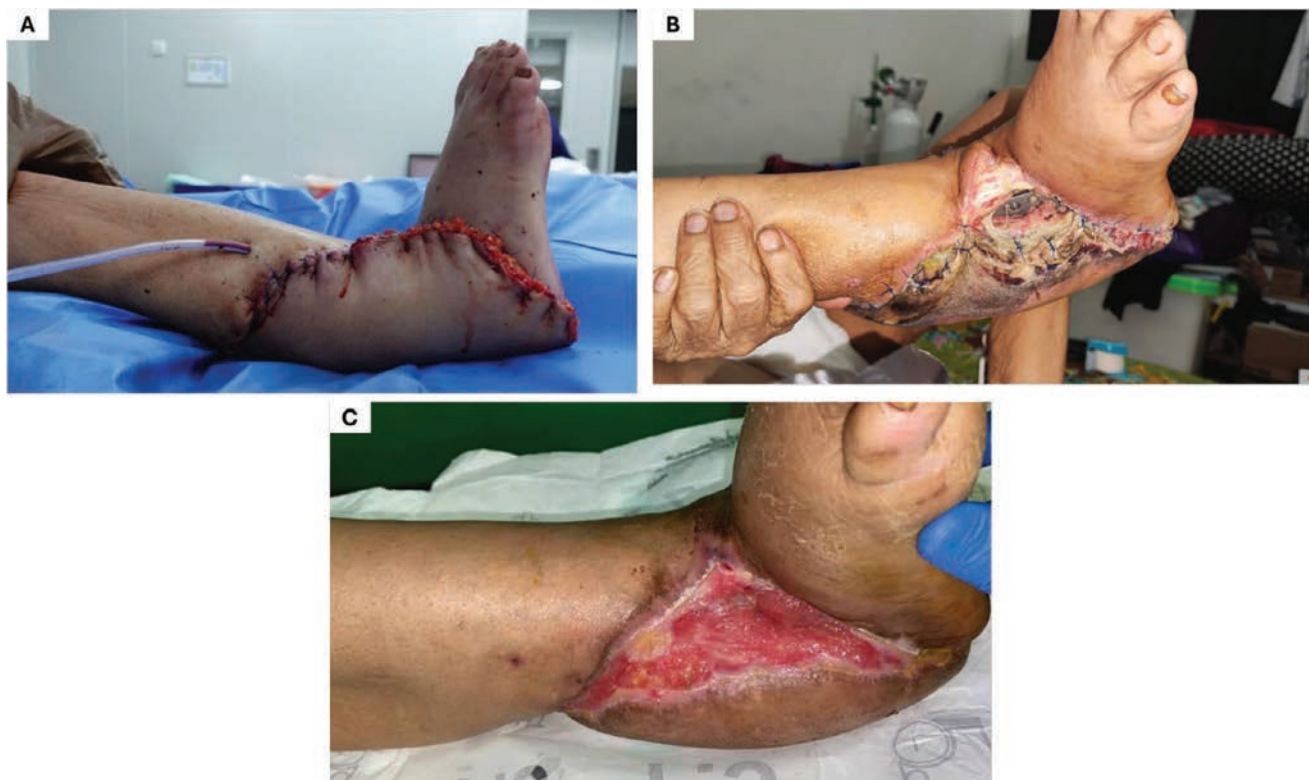
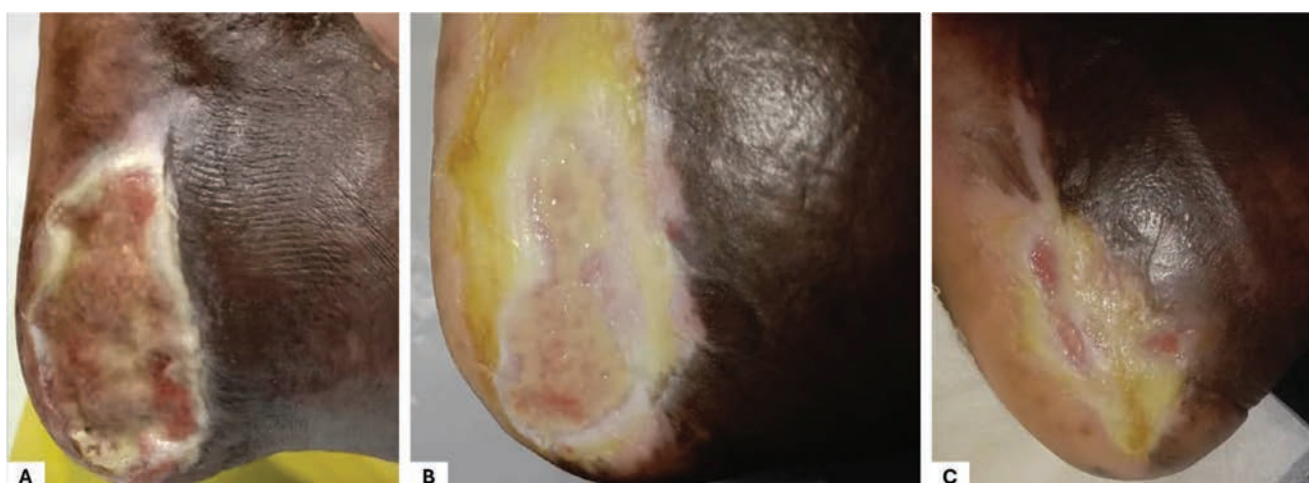
Figure 11. Wound healing demonstrated in a diabetic foot ulcer which improved with 90% epithelialization over 7 weeks following wound debridement, Dermatrix® Wound Care (DWC) gel and shockwave therapy. (A) At presentation. (B) At 3 weeks with DWC gel alone (following debridement). (C) At 7 weeks (with the addition of three weekly sessions of shockwave therapy).



interferon therapy, showed no significant improvement despite several months of negative pressure therapy and 40 cycles of hyperbaric oxygen therapy (Case 16; Figure 16A). The ulcer improved markedly over 4 months,

and the edges became flat and flush with the ulcer following conservative wound debridement, gentle removal of slough and topical DWC gel application (Figure 16B,C).

Figure 12. A non-healing ulcer (>2 months) on the plantar aspect of the left forefoot improved with granulation and epithelization in 3 months with Dermatrix® Wound Care gel dressing (changed every other day) after wound debridement. (A) At presentation (after debridement). (B) At 2 months. (C) At 3 months.

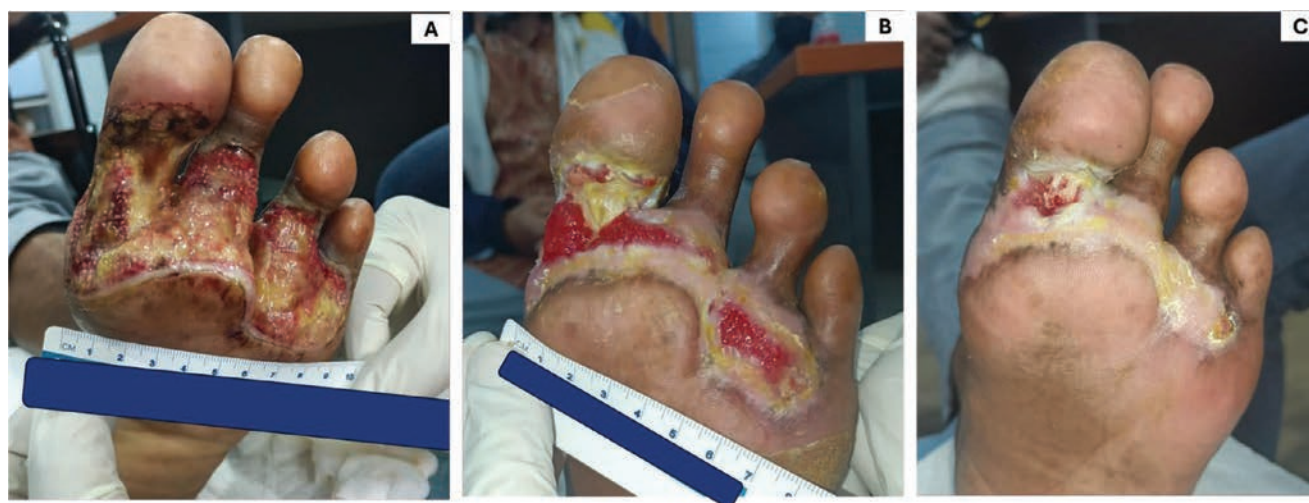
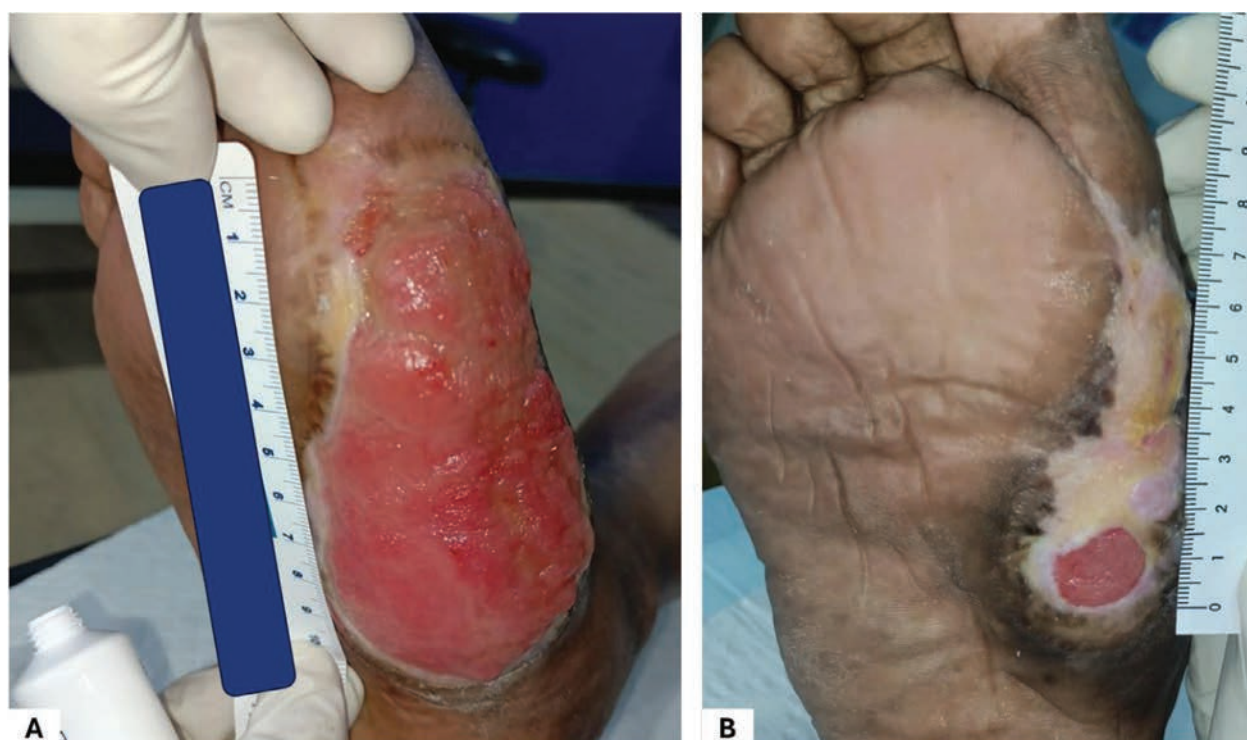

Figure 13. Marked improvement seen over 3 months in a foot ulcer on the medial plantar aspect of the right foot with local mechanical and sharp debridement followed by application of Dermatrix® Wound Care gel and contact layer with superabsorbent foam. (A) At presentation following local and sharp debridement. (B) At 3 months.



Expert opinion

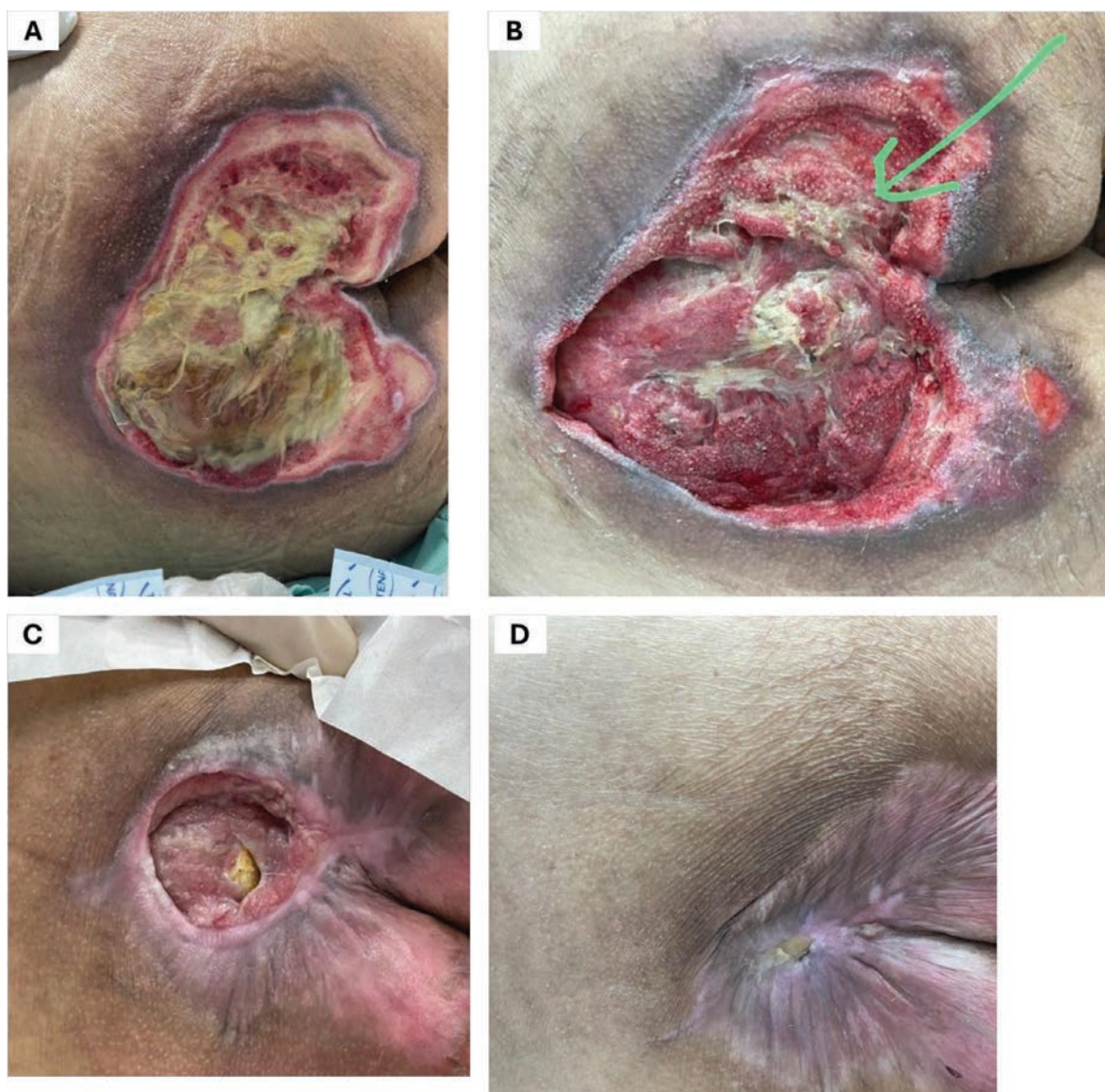
All survey responses are summarized in Table 2.

The expert panel acknowledged that, whilst cleansing the wound alone is not sufficient for wound care and

management, it remains an essential first step in the process (Statement 1). They also unanimously agreed that poor wound care and management could contribute to poor scarring (Statement 2).

Concerning the landscape of wound care management, the panel noted that, though there is an increasing

Figure 14. Marked reduction in the size of a chronic pressure ulcer in the sacral area over 6 months with debridement and negative pressure therapy, followed by Dermatix® Wound Care gel alternating with hydrocolloid paste and silver-based dressing. (A) At presentation. (B) Following debridement. (C) After 3 months of negative pressure therapy with instillation, followed by 3 weeks of no instillation. (D) After 3 months of Dermatix® Wound Care gel alternating with hydrocolloid paste and silver-based dressing.



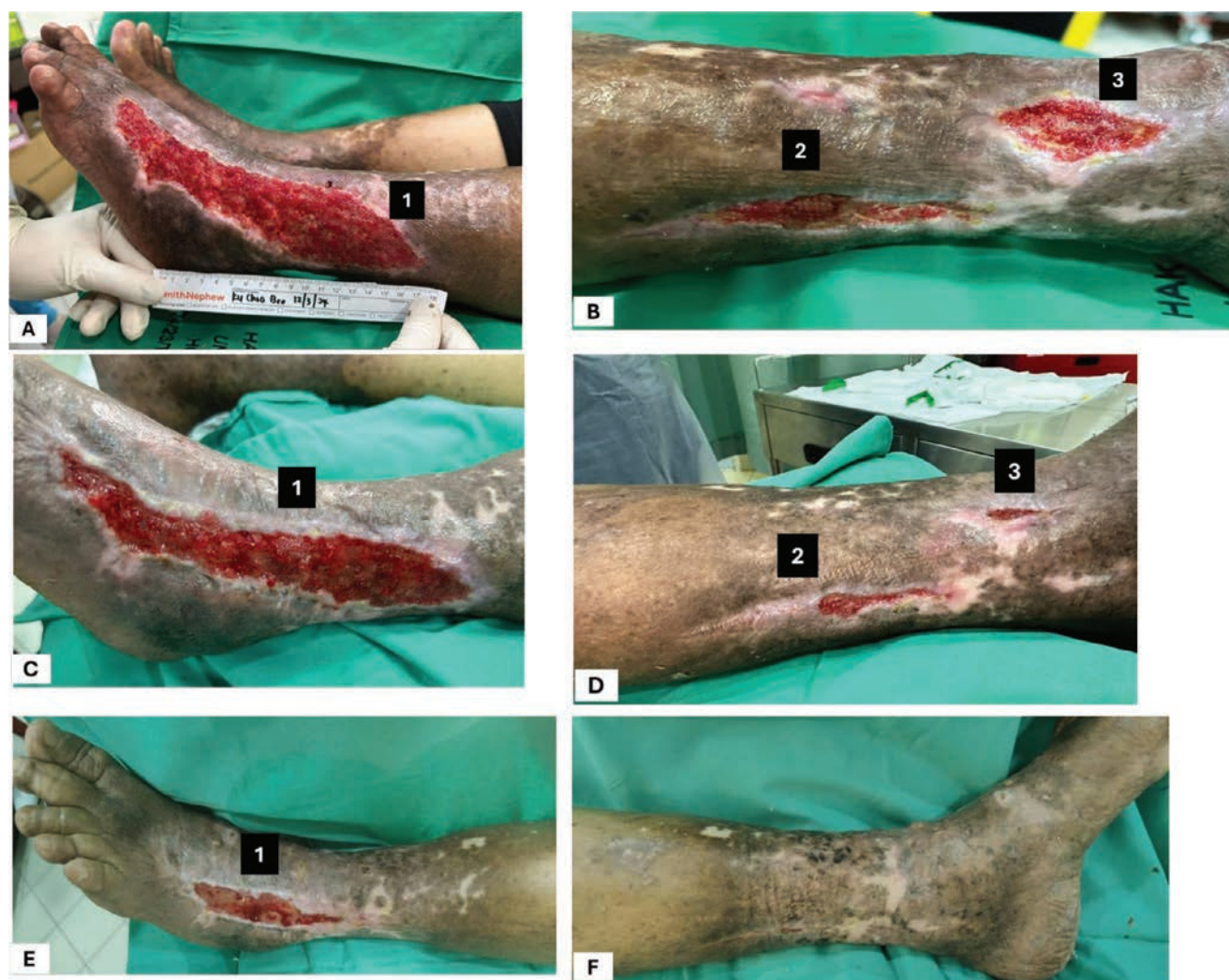understanding of antibiotic resistance among health-care providers, the general public continues to use antibiotic creams for wounds routinely due to a lack of education and awareness, and fear of complications (Statements 3 and 4).

All experts agreed that a moist wound environment promotes wound healing in most wounds; however, for certain wounds, such as arterial wounds or ulcers or gangrenous wounds, a dry environment is more appropriate (Statement 5). Hydrogels provide an optimal moist environment conducive to wound healing. However, improper selection and application without an

understanding of individual constituents could be detrimental (Statements 6 and 7).

The case studies presented by the experts demonstrated that DWC gel helps with granulation and epithelialization and is particularly useful in the third and fourth stages of wound healing – proliferation and remodelling – and accelerates the wound healing process (Statement 8). The experts broadly agreed that DWC gel's intelligent technology seems to help regulate wound moisture but highlighted the need for comparative head-to-head trials *versus* other hydrogels (Statement 9). There was agreement on the impact of carnosine, a key component

Figure 15. Non-healing venous ulcers showed marked improvement following debridement and Dermatrix® Wound Care gel covered with superabsorbent pad dressing and compression bandage for 15 weeks. (A, B) At presentation following debridement. (C, D) At 3 weeks. (E, F) At 12 weeks.



of DWC gel, in accelerating wound healing; further discussion highlighted the need for studies to elucidate the role of carnosine in wound healing (Statement 10). The expert panel also agreed that DWC gel with its white colour allows for good visualization of the demarcation for application on wounds (Statement 11). As elucidated in the case studies, DWC gel appears to provide a cooling effect and pain relief, and reduces itchiness in the wound, but the role of DWC gel in preventing wound infection is not believed to be clearly evidenced and needs further evaluation (Statements 12 and 13). There was unanimous agreement on the safety of DWC gel when used on non-mucosal skin (e.g. trunks, limbs, face) (Statement 14).

The expert panel agreed that DWC gel is suitable for use in (Statements 15, 16 and 17):

- Surgical wounds such as surgical sites (e.g. post-caesarean section and laparotomy) and incisional wounds
- Acute wounds such as abrasion and laceration wounds
- Chronic wounds such as diabetic wounds, pressure injuries and arterial or venous leg ulcers

However, the panel identified certain scenarios where DWC gel may not be appropriate, including fresh surgical wounds, where excess moisture could cause edge maceration, and in infected wounds, where bioburden must first be adequately controlled. On allergy-prone skin, DWC gel should be used on a case-by-case basis – the constituents of the gel need to be carefully considered (Statement 18). A majority of experts also agreed that DWC gel is safe to be used in pregnant or lactating women and children (Statement 19).

Figure 16. Chronic non-healing ulcer on the ankle (>2 years) showed significant improvement over 4 months following conservative wound debridement, silver-based charged fibre dressing for gentle removal of slough, topical Dermatrix® Wound Care gel, and dressing with cotton pads and tubular bandage. (A) Ulcer following conservative debridement. (B) After 1 month. (C) After 3 months.

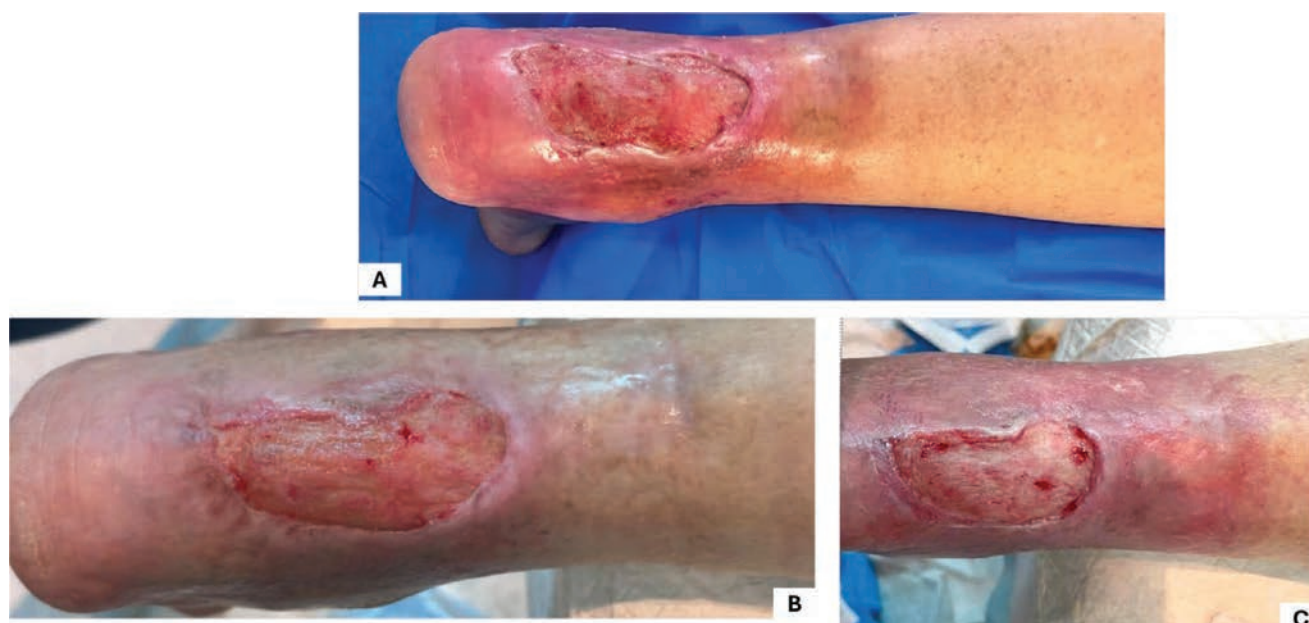


Table 2. Expert opinion.

	Statements	Agree	Somewhat agree	Disagree
1	Wound cleansing alone may not be sufficient for wound care and management.	7	1	0
2	Poor wound care and management could lead to poor scarring.	8	0	0
3	Antiseptic or antibiotics creams are routinely used as household first aid for wound management.	6	2	0
4	Topical antibiotics are often used for wound care without any evidence of infection.	8	0	0
5	Despite available evidence for the benefit of moist wound microenvironment for wound healing, many healthcare professionals prefer to maintain a dry wound microenvironment.	7	1	0
6	Compared to creams, hydrogels provide a better barrier and are more effective in retaining moisture in wounds, making them suitable for use as household first aid for wounds.	7	1	0
7	In both acute and chronic wound management, hydrogels provide an ideal moist microenvironment to support the process of wound healing.	8	0	0
8	DWC gel helps with wound granulation and epithelization (proliferation and remodelling stages) and accelerates wound healing.	8	0	0
9	DWC gel's intelligent hydrogel technology helps to regulate moisture in wound microenvironment better than other types of hydrogels.	6	2	0
10	Carnosine, a key component of DWC gel, provides an added benefit in accelerating wound healing.	7	1	0
11	DWC gel, with its white colour gel, allows good visualization of the demarcation for application on wounds.	8	0	0

(Continued)

Table 2. (Continued)

12	DWC gel provides a cooling effect and pain relief and reduces itchiness in the wound.	8	0	0
13	DWC gel prevents wound infection.	5	3	0
14	DWC gel is generally safe to be used on non-mucosal skin (trunk, limbs, face and so on).	8	0	0
15	DWC gel is suitable to be used in surgical wounds such as surgical sites (e.g., post-caesarean section and laparotomy) and incisional wounds.	8	0	0
16	DWC gel is suitable to be used in acute wounds such as abrasion and laceration wounds.	7	1	0
17	DWC gel is suitable to be used in chronic wounds such as diabetic wounds, pressure injury and arterial/venous leg ulcers.	8	0	0
18	DWC gel is suitable to be used on allergy-prone skin.	7	1	0
19	DWC gel is safe to be used on pregnant/lactating women and children.	6	2	0

DWC, Dermatrix®* Wound Care.

Discussion

Case series

The case series illustrates the efficacy and safety of DWC gel in the management of acute and chronic wounds of varying aetiologies – traumatic, post-procedure complications, allergic dermatitis, post-surgical, diabetic foot ulcers, venous ulcers, vasculitic wounds and pressure ulcers – in real-world settings.

In all the case studies presented, patients were satisfied with the improvement in their wounds; DWC gel was easy and convenient for patients to use at home, and this contributed to good adherence to the regimen. It spreads easily, even on dry and crusted ulcers, and remains adherent to the wound surface for prolonged periods. DWC gel can be used alone as monotherapy (Cases 1 and 2) and can be combined with other modalities, such as shockwave therapy or secondary dressings, as illustrated in cases 4, 10, 11 and 14–16.

In acute superficial wounds, DWC gel promoted wound healing with minimal scarring and little to no post-inflammatory hyperpigmentation; this is cosmetically desirable for most patients (Cases 1–3). In the 16 case studies presented here, as well as in the clinical experience of the expert panel, there were no safety signals, and there were no patient complaints of itching or discomfort with DWC gel.

The results demonstrated in the case series presented here, particularly for superficial wounds, are in line with those seen in a clinical study.¹⁶ A within-person, single-centre, randomized, investigator-blind clinical

study compared a DWC gel-treated test field with an untreated test field in an abrasive wound model. The study reported that treatment of superficial cutaneous wounds with DWC gel resulted in improved wound healing as demonstrated by faster wound closure and a considerably better cosmetic appearance, whilst providing immediate cooling.¹⁶

Chronic wounds, often referred to as a silent epidemic, pose a substantial global burden not only at the individual level but also across healthcare systems worldwide.^{17–19} Whilst data on the prevalence of chronic wounds in Asia remain limited, a recent systematic review and meta-analysis highlights their high prevalence across Asian populations, particularly in resource-constrained settings.¹⁹ The burden of chronic wounds in this region is shaped by socioeconomic factors such as literacy rates, healthcare infrastructure and access to medical services.^{18,19} Given the heterogeneity of populations and healthcare systems across Asian countries, there is a pressing need for region-specific studies to better characterize the epidemiology and impact of chronic wounds. Furthermore, the development of standardized clinical practice guidelines adaptable to local contexts may enhance clinician support and improve the management of chronic wounds in diverse settings.

Through Cases 11–16, we have highlighted the importance of a multimodal, multidisciplinary approach for the effective management of chronic or hard-to-heal wounds, as these wounds are often influenced by a complex interplay of physiological, social and behavioural factors. Collaboration among healthcare professionals, including wound care specialists, dermatologists, surgeons,

nurses and nutritionists, ensures a comprehensive treatment plan that addresses not only the wound itself but also underlying conditions such as diabetes, vascular insufficiency and infection. Patient education plays a pivotal role in this process, empowering patients or their caregivers to adhere to treatment regimens, recognize early signs of complications, and adopt lifestyle modifications that support healing. The TIMERS framework (Tissue management, Inflammation control, Moisture balance, Edge advancement, Regeneration–Repair, and Social factors) provides a structured approach to managing hard-to-heal wounds. Importantly, social- and patient-related factors, such as socioeconomic status, access to healthcare, adherence to treatment and mental health, significantly influence wound healing outcomes.²⁰ Addressing these barriers through tailored patient support, improved healthcare accessibility, and multidisciplinary collaboration enhances the efficacy of wound care strategies, ultimately leading to better healing and quality of life for patients.

Expert opinion

Overall, there was agreement that DWC gel promotes wound healing in acute and chronic wounds. However, there are unmet needs and challenges that need to be addressed, and the expert panel recommended further studies or investigations, including head-to-head clinical trials comparing the effect of DWC gel in wound moisture regulation *versus* that of other hydrogels.

Furthermore, laboratory studies to assess the anti-infective and anti-inflammatory properties of DWC gel, particularly carnosine, will also shed light on the impact of this component. Carnosine, an endogenous dipeptide (constitutive amino acids: L-histidine and β -alanine), has a multimodal mechanism of action, including anti-aggregant, anti-inflammatory and antioxidant properties.^{21,22} It acts as an L-histidine precursor, thus regulating histamine synthesis during trauma; faster wound healing through histamine is associated with the activity of basic fibroblast growth factor, leading to macrophage recruitment and angiogenesis; carnosine also stimulates collagen biosynthesis through the β -alanine component.^{23,24} In animal models, carnosine has been shown to promote wound healing,^{25–27} but further studies to characterize the role of carnosine in wound healing in humans are warranted.

Limitations

The opinion and experience presented in this paper are based on early use of DWC gel, and whilst the findings provide valuable preliminary insights, longer-term use will provide deeper insights and a more comprehensive understanding of its performance and potential applications. The expert panel consisted of eight wound care specialists who contributed two case studies from their respective practices. Whilst the case series and the expert opinion provide a representative perspective of wound care practices in the Asia region, the reliance on anecdotal data and the small sample size limit the generalizability of the findings and have the potential to introduce bias. Additionally, the case studies reflect real-world clinical experiences from different countries and healthcare settings, leading to variability in wound assessment and image documentation. This inconsistency may impact the comparability of cases. Last, outcomes in the case studies were not assessed using objective efficacy measures or validated wound assessment tools, limiting the ability to quantify the impact of DWC gel on wound healing outcomes. Future studies with larger sample sizes, standardized wound assessment protocols and objective outcome measures are warranted to validate these preliminary observations.

Conclusion

This case series of acute and chronic wounds, including traumatic wounds, post-procedure complications, post-surgical wounds, diabetic foot ulcers, venous ulcers, vasculitic wounds and pressure ulcers, demonstrated the efficacy and safety of DWC gel in wound care and management. The expert opinion, based on the clinical experience of the panel, supports the use of DWC gel for managing acute and chronic wounds, alone and with other modalities of treatment as appropriate. A collaborative wound management approach is crucial for managing chronic or hard-to-heal wounds as these are influenced by a complex interplay of physiological, social and behavioural factors. Utilizing the TIMERS framework, enhancing patient education, and addressing social determinants of health through tailored support and collaboration can significantly improve wound healing outcomes and overall patient well-being.

Contributions: All authors contributed equally to the preparation of this manuscript. All named authors meet the International Committee of Medical Journal Editors (ICMJE) criteria for authorship for this article, take responsibility for the integrity of the work as a whole, and have given their approval for this version to be published. The authors decline the use of artificial intelligence, language models, machine learning, or similar technologies to create content or assist with writing or editing of the manuscript.

Disclosure and potential conflicts of interest: CYL, EWHC, VK, DT, WL, VAL and TPTV have no conflicts of interest to declare. KYC declares receiving honorarium for attending the roundtable meeting held by A. Menarini. KCW is an employee of A. Menarini Singapore. The International Committee of Medical Journal Editors (ICMJE) Potential Conflicts of Interests form for the authors is available for download at: <https://www.drugsincontext.com/wp-content/uploads/2025/12/dic.2025-8-3-COI.pdf>

Acknowledgements: Editorial assistance for the preparation of the manuscript was provided by Dr Shilpa Mudgal from In Vivo Communications Asia Pte Ltd. This editorial support was funded by A. Menarini Asia-Pacific Pte Ltd. and complied with the international guidelines for Good Publication Practice (GPP3). VAL acknowledges the support received from Professor Le Thai Van Thanh (University of Medicine and Pharmacy, Ho Chi Minh City, Vietnam) for the management of the cases presented herein.

Funding declaration: Editorial assistance for the development of the manuscript and all tasks related to organization of the virtual meeting were funded by A. Menarini Asia-Pacific Pte Ltd. The cases presented herein are based exclusively on the real-world, clinical treatment experiences of the contributing physicians and do not represent or promote A. Menarini's opinions or preferences. Please refer to the detailed package insert/instruction for use for complete prescribing information.

Copyright: Copyright © 2026 Lee CY, Chang EWH, Chew KY, Karupayah V, Latief W, Vi Le A, Tobing D, Vu TPT, Wong KC. Published by *Drugs in Context* under Creative Commons License Deed CC BY NC ND 4.0, which allows anyone to copy, distribute, and transmit the article provided it is properly attributed in the manner specified below. No commercial use without permission.

Correct attribution: Copyright © 2026 Lee CY, Chang EWH, Chew KY, Karupayah V, Latief W, Vi Le A, Tobing D, Vu TPT, Wong KC. <https://doi.org/10.7573/dic.2025-8-3>. Published by *Drugs in Context* under Creative Commons License Deed CC BY NC ND 4.0.

Article URL: <https://www.drugsincontext.com/role-of-a-topical-hydrogel-dermatix-wound-care-gel-in-acute-and-chronic-wound-management-a-case-series-of-real-world-experiences-and-expert-opinion-from-asia>

Correspondence: Chin Yen Lee, Wound Care Unit, Department of Orthopaedics, Hospital Tengku Ampuan Afzan, Kuantan, Pahang, Malaysia. Email: leechinyen@malaysiawoundclinician.com

Provenance: Submitted; externally peer reviewed.

Submitted: 7 August 2025; **Accepted:** 26 November 2025; **Published:** 20 January 2026.

Drugs in Context is published by BioExcel Publishing Ltd. Registered office: 6 Green Lane Business Park, 238 Green Lane, New Eltham, London, SE9 3TL, UK.

BioExcel Publishing Limited is registered in England Number 10038393. VAT GB 252 7720 07.

For all manuscript and submissions enquiries, contact the Editorial office editorial@drugsincontext.com

For all permissions, rights, and reprints, contact David Hughes david.hughes@bioexcelpublishing.com

References

1. Winter GD. Formation of the scab and the rate of epithelization of superficial wounds in the skin of the young domestic pig. *Nature*. 1962;193:293–294. <https://doi.org/10.1038/193293a0>
2. Olutoye OO, Eriksson E, Menchaca AD, et al. Management of acute wounds-expert panel consensus statement. *Adv Wound Care*. 2024;13(11):553–583. <https://doi.org/10.1089/wound.2023.0059>

3. Schultz G, Tariq G, Harding K, et al. WUWHS Consensus Document – wound exudate, effective assessment and management. Wounds International, 2019. <https://woundsinternational.com/wp-content/uploads/2023/02/836aed9753c3d8e3d8694bcaee336395.pdf>. Accessed February 2025.
4. Atiyeh BS, Hayek SN. An update on management of acute and chronic open wounds: the importance of moist environment in optimal wound healing. *Med Chem Rev.* 2004;1(2):111–121. <https://doi.org/10.2174/1567203043480304>
5. Korting HC, Schöllmann C, White RJ. Management of minor acute cutaneous wounds: importance of wound healing in a moist environment. *J Eur Acad Dermatol Venereol.* 2011;25(2):130–137. <https://doi.org/10.1111/j.1468-3083.2010.03775.x>
6. Mirhaj M, Labbaf S, Tavakoli M, Seifalian AM. Emerging treatment strategies in wound care. *Int Wound J.* 2022;19(7):1934–1954. <https://doi.org/10.1111/iwj.13786>
7. Nuutila K, Eriksson E. Moist Wound healing with commonly available dressings. *Adv Wound Care.* 2021;10(12):685–698. <https://doi.org/10.1089/wound.2020.1232>
8. Nguyen HM, Ngoc Le TT, Nguyen AT, Thien Le HN, Pham TT. Biomedical materials for wound dressing: recent advances and applications. *RSC Adv.* 2023;13(8):5509–5528. <https://doi.org/10.1039/d2ra07673j>
9. Brumberg V, Astrelina T, Malivanova T, Samoilov A. Modern wound dressings: hydrogel dressings. *Biomedicines.* 2021;9(9):1235. <https://doi.org/10.3390/biomedicines9091235>
10. Bowers S, Franco E. Chronic wounds: evaluation and management. *Am Fam Physician.* 2020;101(3):159–166.
11. Tan ST, Dosan R. Lessons from epithelialization: the reason behind moist wound environment. *Open Dermatol J.* 2019;13(1):34–40. <https://doi.org/10.2174/1874372201913010034>
12. Bahram M, Mohseni N, Moghtader M. An introduction to hydrogels and some recent applications. In: Majee S, ed. *Emerging Concepts in Analysis and Applications of Hydrogels*. InTech; 2016. <https://www.intechopen.com/chapters/51535>. Accessed February 2025.
13. Rütter L, Voss W. Hydrogel or ointment? Comparison of five different galenics regarding tissue breathability and transepidermal water loss. *Heliyon.* 2021;7(1):e06071. <https://doi.org/10.1016/j.heliyon.2021.e06071>
14. Xiang J, Shen L, Hong Y. Status and future scope of hydrogels in wound healing: synthesis, materials and evaluation. *Eur Polym J.* 2020;130:109609. <https://doi.org/10.1016/j.eurpolymj.2020.109609>
15. Aswathy SH, Narendrakumar U, Manjubala I. Commercial hydrogels for biomedical applications. *Heliyon.* 2020;6(4):e03719. <https://doi.org/10.1016/j.heliyon.2020.e03719>
16. Zhang L, de Salvo R, Trapp S, et al. Evaluation of BepanGel hydrogel efficacy and tolerability using an abrasive wound model in a within-person, single-center, randomized, investigator-blind clinical investigation. *Dermatol Ther.* 2020;10(5):1075–1088. <https://doi.org/10.1007/s13555-020-00432-5>
17. Graves N, Ganesan G, Tan KB, et al. Chronic wounds in a multiethnic Asian population: a cost of illness study. *BMJ Open.* 2023;13(9):e065692. <https://doi.org/10.1136/bmjopen-2022-065692>
18. Maheshwari G. Chronic wounds: a rising public health concern. *Wounds APAC.* 2024;7(1):7–11.
19. Burhan A, Syafiqah N, Ruangdet K, et al. Hidden wounds: prevalence of chronic wounds in Asia, a systematic review and meta-analysis. *JNJ.* 2025;3(3):230–245. <https://doi.org/10.61716/jnj.v3i3.117>
20. Atkin L, Bučko Z, Conde Montero E, et al. Implementing TIMERS: the race against hard-to-heal wounds. *J Wound Care.* 2019;23(Sup3a):S1–S50. <https://doi.org/10.12968/jowc.2019.28.Sup3a.S1>
21. Boldyrev AA, Aldini G, Derave W. Physiology and pathophysiology of carnosine. *Physiol Rev.* 2013;93(4):1803–1845. <https://doi.org/10.1152/physrev.00039.2012>
22. Bonaccorso A, Privitera A, Grasso M, et al. The therapeutic potential of novel carnosine formulations: perspectives for drug development. *Pharmaceuticals.* 2023;16(6):778. <https://doi.org/10.3390/ph16060778>
23. Fitzpatrick DW, Fisher H. Carnosine, histidine, and wound healing. *Surgery.* 1982;91(1):56–60.
24. Numata Y, Terui T, Okuyama R, et al. The accelerating effect of histamine on the cutaneous wound-healing process through the action of basic fibroblast growth factor. *J Invest Dermatol.* 2006;126(6):1403–1409. <https://doi.org/10.1038/sj.jid.5700253>
25. Ansurudeen I, Sunkari VG, Grünler J, et al. Carnosine enhances diabetic wound healing in the db/db mouse model of type 2 diabetes. *Amino Acids.* 2012;43(1):127–134. <https://doi.org/10.1007/s00726-012-1269-z>
26. Nagai K, Suda T, Kawasaki K, Mathuura S. Action of carnosine and beta-alanine on wound healing. *Surgery.* 1986;100(5):815–821.
27. Perel'man MI, Kornilova ZKh, Paukov VS, Boikov AK, Priimakov AA. Vliianie karnozina na zazhivlenie rany legkogo [The effect of carnosine on the healing of a lung wound]. *Biull Eksp Biol Med.* 1989;108(9):352–356. [Article in Russian].