

CASE REPORT

New treatment options for advanced endometrial carcinoma Special Issue

Sustained disease control with pembrolizumab–lenvatinib in a patient with heavily pre-treated recurrent endometrial carcinoma: a case report

Alessia Lancianese¹, Elena Maccaroni², Laura Zepponi², Riccardo Giampieri¹, Rossana Berardi¹

¹Oncologia Medica, Università Politecnica delle Marche, Ancona, Italy; ²Oncologia Medica, Azienda Ospedaliero Universitaria delle Marche, Ancona, Italy

Abstract

Advanced endometrial carcinoma (EC) is typically associated with poor prognosis. However, recent advances have revolutionized therapeutic strategies. In patients with microsatellite stable (MSS) advanced EC, pembrolizumab plus lenvatinib have significantly improved overall survival, progression-free survival and response rate compared to standard chemotherapy. We describe the case of a 63-year-old woman with advanced endometrioid adenocarcinoma exhibiting mismatch repair proficiency (pMMR) and MSS who started treatment with pembrolizumab and lenvatinib after failing multiple lines of therapy. The patient had a favourable response, with mild side effects, and continues to receive treatment. Our experience supports pembrolizumab plus lenvatinib as a promising therapeutic option for patients with advanced recurrent EC with pMMR/MSS.

This article is part of the *New treatment options for advanced endometrial carcinoma* Special Issue: https://www.drugsincontext.com/special_issues/new-treatment-options-for-advanced-endometrial-carcinoma

Keywords: cancer, endometrial, immunotherapy, microsatellite-stable, proficient mismatch repair.

Citation

Lancianese A, Maccaroni E, Zepponi L, Giampieri R, Berardi R. Sustained disease control with pembrolizumab–lenvatinib in a patient with heavily pre-treated recurrent endometrial carcinoma: a case report. *Drugs Context*. 2025;14:2025-4-6. <https://doi.org/10.7573/dic.2025-4-6>

Introduction

Endometrial carcinoma (EC) represents the sixth most common cancer in women worldwide.¹ The most frequent histological sub-type is represented by endometrioid adenocarcinoma. Recently, based on molecular classification, ECs have been divided into four specific sub-types: *POLE* ultra mutated, with the most favourable prognostic profile; microsatellite instability (MSI) hypermutated (mismatch repair-deficient (dMMR)), with intermediate prognosis; copy number low (MMR-proficient (pMMR)); and copy number high, often harbouring *p53* mutation, with the worst prognosis.¹ In addition to having a prognostic role, this classification can also lead to tailored therapy. Approximately 10–15% of patients with EC present with advanced-stage disease, and 5-year survival amongst this sub-group of patients is reported at approximately 17%.¹

In patients with EC with advanced or recurrent disease who progressed to first-line platinum-based chemotherapy combinations, only a few therapeutic options are currently available. The KEYNOTE-146 trial demonstrated the efficacy of combining lenvatinib (an oral multi-kinase inhibitor targeting vascular endothelial growth factor receptors 1–3, fibroblast growth factor receptors 1–4 and platelet-derived growth factor- β) with pembrolizumab immunotherapy (a humanized monoclonal antibody that targets programmed cell death protein 1 (PD-1)), in patients with disease progression following at least one prior platinum-based therapy.² Immunohistochemical analyses conducted by Vanderstraeten et al.³ showed that programmed cell death 1 ligand 1 (PD-L1) is expressed in 83% of primary endometrial tumours and in 100% of metastatic lesions. Pembrolizumab, as an anti-PD-1 antibody, enhances immune-mediated tumour cell killing,

whilst lenvatinib, a tyrosine kinase inhibitor, exerts anti-angiogenic effects by targeting multiple pathways involved in tumour growth and vascularization. Patients with advanced pMMR/microsatellite stable (MSS) EC had significantly longer progression-free survival (PFS) with lenvatinib plus pembrolizumab (median 7.2 *versus* 3.8 months, HR 0.56, 95% CI 0.47–0.66; $p < 0.001$) than with chemotherapy alone. Moreover, overall survival (OS) in the pMMR population was significantly longer with lenvatinib plus pembrolizumab (median 18.3 *versus* 11.4 months, HR 0.62, 95% CI 0.51–0.75; $p < 0.001$) than with chemotherapy alone.³

We present a case of advanced pMMR/MSS EC that was successfully treated with pembrolizumab plus lenvatinib after chemotherapy failure. The patient has given consent for the publication of the manuscript.

Case report

In July 2014, a 53-year-old woman underwent total abdominal hysterectomy and bilateral salpingo-oophorectomy. The histopathological report showed well-differentiated (G1) pT1a (according to FIGO staging⁴) endometrial adenocarcinoma with pMMR/MSS. Following surgical resection, she commenced regular gynaecological and oncological follow-ups.

In November 2017, she presented to our outpatient clinic following a CT scan performed in September 2017, which had been conducted to investigate mild abdominal pain. The imaging revealed multiple intra-abdominal peritoneal lesions with the largest located adjacent to the middle third of the right ureter. A biopsy confirmed that these lesions were metastases from hormone receptor-positive EC, showing 80% expression for both oestrogen and progesterone receptors. To address the ureteral compression caused by the largest lesion, a right ureteral stent was placed.

From November 2017 to April 2018, the patient underwent first-line chemotherapy consisting of six cycles of carboplatin (AUC 5) combined with paclitaxel (175 mg/m²), administered every 3 weeks. This treatment resulted in a partial response, as evidenced by follow-up CT scans. In May 2018, given the tumour's positive oestrogen receptor expression, she initiated maintenance therapy with megestrol acetate at a dose of 160 mg daily.

In August 2018, a CT scan revealed the progression of the peritoneal disease. As a result, she began second-line chemotherapy with pegylated liposomal doxorubicin in September 2018. She received a total of 12 cycles, achieving a partial response. Following this, she transitioned to hormonal-based maintenance therapy with letrozole.

Additionally, in September 2019, due to extensive calcification, the right ureteral stent was removed. The patient continued letrozole therapy from October 2019 to October 2021. However, in June 2021, a CT scan demonstrated progressive disease with an isolated lesion identified near the right ureter. This finding was further confirmed by PET in August 2021.

After multidisciplinary consultation, it was decided to proceed with radiotherapy targeting the site of oligo-progressive disease, whilst continuing hormonal therapy. In August 2021, she underwent five sessions of radiotherapy directed at the ureteral metastasis, receiving a total dose of 3,500 cGy, administered as 700 cGy per day over five fractions.

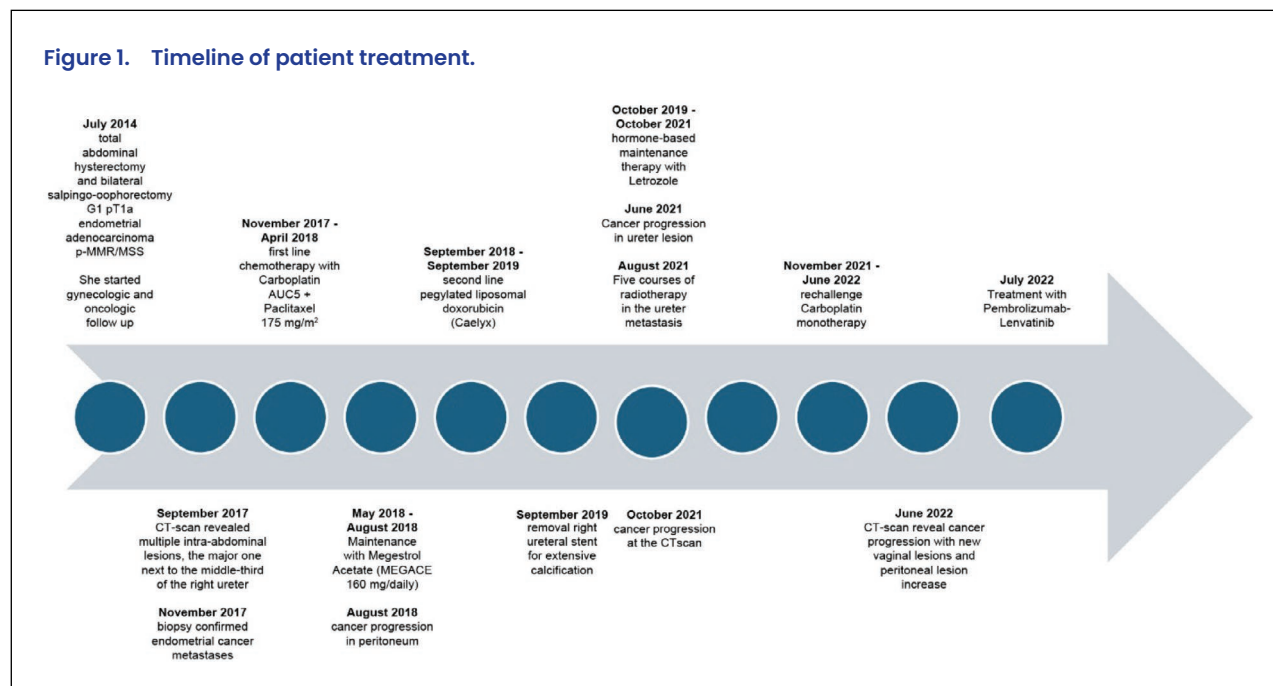
In October 2021, CT-scan showed further cancer progression in the middle-third ureter lesion.

Starting November 2021 till June 2022, the patient underwent re-challenge chemotherapy with carboplatin monotherapy for nine cycles. Carboplatin monotherapy was discontinued after the CT scan, June 2022, demonstrated disease progression, evidenced by the development of new vaginal lesions and an increase in peritoneal disease burden.

The case was re-evaluated during a multidisciplinary meeting in July 2022. Considering the failure of multiple lines of chemotherapy and the presence of pMMR EC, the team recommended initiating treatment with pembrolizumab at a dose of 200 mg every 3 weeks in combination with lenvatinib 20 mg daily. This decision was made following a comprehensive cardiological assessment, which ruled out any potential contraindications to the proposed therapy.

During the first 2 months of treatment with the combination of pembrolizumab and lenvatinib, the patient experienced gastrointestinal toxicity, presenting with grade 3 diarrhoea and nausea according to National Cancer Institute Common Terminology Criteria for Adverse Events. This led to a temporary interruption of lenvatinib for 1 week. Treatment was subsequently resumed with a reduced lenvatinib dose of 14 mg daily, whilst pembrolizumab was continued at the standard dose of 200 mg every 3 weeks. However, due to the persistence of nausea and diarrhoea, an additional dose reduction of lenvatinib to 10 mg daily was required.

Treatment with the personalized dose of lenvatinib 10 mg/day and pembrolizumab 200 mg every 3 weeks was well tolerated, with complete resolution of gastrointestinal toxicity. Other adverse effects were haematological toxicity (grade 1 anaemia) and endocrinolog-

Figure 1. Timeline of patient treatment.

ical toxicity, particularly hypothyroidism, managed with endocrine replacement therapy.

The CT scan performed after 3 months of treatment showed stable disease. Our patient has continued treatment with lenvatinib 10 mg daily and pembrolizumab 200 mg every 3 weeks for more than 2 years without any other significant side effects. She remains on treatment with stable disease observed in the most recent CT scan conducted in September 2024. The timeline of treatment is summarized in Figure 1.

Discussion

In 2013, the Cancer Genome Atlas project analysed approximately 400 different EC genomes using array-based and sequencing-based technologies leading to the reclassification of EC into four distinct clusters based on genomic profiles.¹ Notably, the 'copy number low' subgroup represents 39% of EC cases, and within this group, pMMR/MSS adenocarcinomas are often present, frequently exhibiting positive oestrogen and progesterone receptor expression. The treatment of this group of patients has evolved with the introduction of immunotherapy. Specifically, patients with dMMR or MSI-high (MSI-H) EC have shown significant benefit from immunotherapy in the first-line setting as well as in recurrent disease.⁵⁻⁷

The difference in benefit achieved by immunotherapy between patients with dMMR/MSI-H tumours and those with pMMR/MSS tumours can be partly explained by the role of the DNA MMR system. This cellular repair mecha-

nism ensures genomic stability at microsatellites by preventing DNA insertions or deletions. Defects in MMR and the resulting MSI can lead to an increased tumour mutational burden. Tumours with a higher tumour mutational burden are typically associated with a greater likelihood of responding to immune-checkpoint blockade therapies. Pembrolizumab monotherapy has shown less activity in patients with MSS or pMMR disease than in those with MSI-H or dMMR disease.⁷ Only 30% of EC cases presenting with the MSI-H phenotype and 70% of EC are MSS and have limited treatment options in the recurrent setting. In MSS EC, the combination of anti-PD-1 immunotherapy with anti-angiogenesis represents an intriguing therapeutic strategy. This approach leverages the potential role of anti-angiogenesis therapy in modulating the tumour immune microenvironment, which can enhance the effectiveness of anti-PD-1 immunotherapy through a synergistic effect.⁸

Indeed, the KEYNOTE-146 phase Ib/II study demonstrated promising efficacy and tolerable safety in patients with previously treated advanced EC who were treated with the combination of pembrolizumab and lenvatinib. Patients with advanced pMMR/MSS EC have significantly longer PFS with lenvatinib plus pembrolizumab (median 6.6 months, 95% CI 5.6–7.4) than with chemotherapy alone (median 3.8 months, 95% CI 3.6–5.0). Moreover, OS in the pMMR population was significantly longer with lenvatinib plus pembrolizumab (median 17.4 months, 95% CI 14.2–19.9) than with chemotherapy alone (median 12.0 months, 95% CI 10.8–13.3).²

The KEYNOTE-775 study with lenvatinib plus pembrolizumab combination confirmed the efficacy data from

KEYNOTE-146 in terms of both PFS and OS irrespective of MMR status.⁹ Therefore, patients presenting with advanced EC pMMR/MSS obtained an important benefit from the combination of pembrolizumab and lenvatinib.

The promising results reported in the KEYNOTE 146 study were also confirmed by the KEYNOTE-775 trial, which was the first phase III randomized study to show a statistically significant improvement in OS (HR 0.62, 95% CI 0.51–0.75; $p < 0.0001$), PFS (HR 0.56, 95% CI 0.47–0.66; $p < 0.0001$) and ORR (31.9% *versus* 14.7%) compared to standard chemotherapy in patients with previously treated, recurrent advanced EC, therefore meeting its dual primary endpoints. The secondary endpoint was also met, and this was observed not only in patients with dMMR/MSI-H EC but also in those with pMMR/MSS.⁷

These important and clinically relevant results led both the FDA and EMA to approve this regimen for the treatment of advanced or recurrent EC in patients not eligible for curative surgery or radiotherapy who have disease progression on or following prior treatment with a platinum-containing therapy in any setting regardless of MMR status. The management of pMMR/MSS EC also presents with a series of limitations such as health economic implications. A cost-effectiveness analysis of pembrolizumab plus lenvatinib for recurrent/advanced EC showed that it is not more cost-effective than chemotherapy.¹⁰ For patients with pMMR EC, the combination had an incremental cost-effectiveness ratio of US\$413,256.68 per quality-adjusted life-year compared to US\$378,251.44 per quality-adjusted life-year for chemotherapy. Key factors influencing this were PFS, OS and the cost of combination therapy. Reducing pembrolizumab and lenvatinib prices could improve cost-effectiveness. However, comparing this combination to standard treatment is complex, as many patients suitable for it may not tolerate chemotherapy. A recently published analysis further supports this point, showing that the time to definitive deterioration of symptoms was longer for patients treated with the lenvatinib and pembrolizumab combination compared to chemotherapy, suggesting that the combination therapy offers a more favourable benefit–risk profile than chemotherapy in patients with advanced EC.¹¹

Here, we report on the case of a patient who achieved significant benefit from pembrolizumab/lenvatinib treatment. The patient, diagnosed with pMMR/MSS EC, was successfully treated with this combination after failure of multiple lines of chemotherapy and hormonal therapy, including a platinum rechallenge. Pembrolizumab/lenvatinib treatment was initiated in July 2022 and is still ongoing. The patient experienced manageable adverse effects, with the most significant being gastrointestinal toxicity (grade 3), including nausea, vomiting and diarrhoea, which required a dose reduction of lenvatinib. The KEYNOTE-775 study demonstrated that dose reduction of lenvatinib due to toxicity does not reduce the drug's effectiveness. In our case, the dose reduction (from 20 mg daily to 14 mg, and then 10 mg daily) allowed the patient to continue treatment without cancer progression. Moreover, our patient represents an interesting case of late metastasis following early-stage EC. At diagnosis, she had well-differentiated (G1), pT1a EC, and a single inguinal lymph node was examined, showing no metastasis. However, 3 years later, a CT scan revealed intra-abdominal peritoneal metastases. Metastases in early-stage EC are uncommon and, typically, lymphadenectomy is not recommended during surgery for pT1a stage EC due to the low risk of lymphatic spread.

Conclusion

Our patient represents a successful case demonstrating the effectiveness of a new treatment regimen in recurrent pMMR/MSS EC using the combination of pembrolizumab and lenvatinib with manageable adverse effects. Despite favourable tumour biology, as indicated by the relatively slow and non-aggressive progression of disease, she had already exhausted all available treatment modalities before starting pembrolizumab and lenvatinib. Yet, she benefited from this combination, remaining on therapy for over 2 years. This combination of pembrolizumab immunotherapy and the oral multi-kinase inhibitor lenvatinib offers a viable and manageable strategy for the treatment of advanced recurrent EC regardless of MMR status.

Contributions: EM and LZ managed the patient's clinical care. AL and EM designed the case study. AL analysed the recent literature and wrote the manuscript. RG reviewed the manuscript. All named authors meet the International Committee of Medical Journal Editors (ICMJE) criteria for authorship for this article, take responsibility for the integrity of the work as a whole, and have given their approval for this version to be published.

Disclosure and potential conflicts of interest: AL and LZ declare no conflicts of interest. EM is an advisory board participant for MSD, AstraZeneca, GSK, Eisai and Clovis and has received support for attending meetings from MSD

Italia, AstraZeneca, Sophos Biotech and Janssen Cilag SPA. RG is an advisory board participant for MSD, AstraZeneca, Daiichi-Sankyo, Merck-Serono and Servier and has received support for attending meetings from Servier, AstraZeneca, MSD and Merck-Serono. RB has received consulting fees from Bayer, Boehringer Ingelheim, Eisai, Lilly, Menarini and GSK and received equipment, gifts or other services to their institution from AstraZeneca, Pfizer and Roche. The International Committee of Medical Journal Editors (ICMJE) Potential Conflicts of Interests form for the authors is available for download at: <https://www.drugsincontext.com/wp-content/uploads/2025/05/dic.2025-4-6-COI.pdf>

Acknowledgements: AL would like to thank Dr Maccaroni and Dr Zepponi for getting them interested in gynecological cancers, Prof. Giampieri for his teachings and Prof. Berardi for providing the opportunity to participate in this work. Thanks to the patient for giving consent to use their data for this case report.

Funding declaration: There was no funding associated with the preparation of this article.

Copyright: Copyright © 2025 Lancianese A, Maccaroni E, Zepponi L, Giampieri R, Berardi R. Published by *Drugs in Context* under Creative Commons License Deed CC BY NC ND 4.0, which allows anyone to copy, distribute, and transmit the article provided it is properly attributed in the manner specified below. No commercial use without permission.

Correct attribution: Copyright © 2025 Lancianese A, Maccaroni E, Zepponi L, Giampieri R, Berardi R. <https://doi.org/10.7573/dic.2025-4-6>. Published by *Drugs in Context* under Creative Commons License Deed CC BY NC ND 4.0.

Article URL: <https://www.drugsincontext.com/sustained-disease-control-with-pembrolizumab-lenvatinib-in-a-patient-with-heavily-pre-treated-recurrent-endometrial-carcinoma-a-case-report>

Correspondence: Alessia Lancianese, Oncologia Medica, Università Politecnica delle Marche, Ancona, Italy. Email: ale.lancii96@gmail.com

Provenance: Submitted; externally peer reviewed.

Submitted: 13 April 2025; **Accepted:** 5 May 2025; **Published:** 24 June 2025.

Drugs in Context is published by BioExcel Publishing Ltd. Registered office: 6 Green Lane Business Park, 238 Green Lane, New Eltham, London, SE9 3TL, UK.

BioExcel Publishing Limited is registered in England Number 10038393. VAT GB 252 7720 07.

For all manuscript and submissions enquiries, contact the Editorial office editorial@drugsincontext.com

For all permissions, rights, and reprints, contact David Hughes david.hughes@bioexcelpublishing.com

References

1. The Cancer Genome Atlas Research Network, Weinstein J, Collisson E et al. The Cancer Genome Atlas Pan-Cancer analysis project. *Nat Genet.* 2013;45:1113–1120. <https://doi.org/10.1038/ng.2764>
2. Makker V, Aghajanian C, Cohn AL, et al. A phase Ib/II study of lenvatinib and pembrolizumab in advanced endometrial carcinoma (Study 111/KEYNOTE-146): long-term efficacy and safety update. *J Clin Oncol.* 2023;41(5):974–979. <https://doi.org/10.1200/JCO.22.01021>
3. Vanderstraeten A, Luyten C, Verbist G, Tuytens S, Amant F. Mapping the immunosuppressive environment in uterine tumors: implications for immunotherapy. *Cancer Immunol Immunother.* 2014;63:545–557. <https://doi.org/10.1007/s00262-014-1537-8>
4. Berek JS, Matias-Guiu X, Creutzberg C, et al. Endometrial Cancer Staging Subcommittee, FIGO Women's Cancer Committee. FIGO staging of endometrial cancer: 2023. *Int J Gynaecol Obstet.* 2023;162:383–394. <https://doi.org/10.1002/ijgo.14923>

5. Powell MA, Bjørge L, Willmott L, et al. Overall survival in patients with endometrial cancer treated with dostarlimab plus carboplatin-paclitaxel in the randomized ENGOT-EN6/GOG-3031/RUBY trial. *Ann Oncol*. 2024;35:728–738. <https://doi.org/10.1016/j.annonc.2024.05.546>
6. Oaknin A, Gilbert L, Tinker AV, et al. Safety and antitumor activity of dostarlimab in patients with advanced or recurrent DNA mismatch repair deficient/microsatellite instability-high (dMMR/MSI-H) or proficient/stable (MMRp/MSS) endometrial cancer: interim results from GARNET-a phase I, single-arm study. *J Immunother Cancer*. 2022;10(1):e003777. <https://doi.org/10.1136/jitc-2021-003777>
7. O'Malley DM, Bariani GM, Cassier PA, et al. Pembrolizumab in patients with microsatellite instability-high advanced endometrial cancer: results from the KEYNOTE-158 study. *J Clin Oncol*. 2022;40:752–761. <https://doi.org/10.1200/JCO.21.01874>
8. Mahdi H, Chelariu-Raicu A, Slomovitz BM. Immunotherapy in endometrial cancer. *Int J Gynecol Cancer*. 2023;33:351–357. <https://doi.org/10.1136/ijgc-2022-003675>
9. Makker V, Colombo N, Casado Herráez A, et al. Lenvatinib plus pembrolizumab for advanced endometrial cancer. *N Engl J Med*. 2022;386:437–448. <https://doi.org/10.1056/NEJMoa2108330>
10. Feng M, Chen Y, Yang Y, Li Q. Lenvatinib plus pembrolizumab vs. chemotherapy in pretreated patients with advanced endometrial cancer: a cost-effectiveness analysis. *Front Public Health*. 2022;10:881034. <https://doi.org/10.3389/fpubh.2022.881034>
11. Lorusso D, Colombo N, Herraez AC, et al. Health-related quality of life in patients with advanced endometrial cancer treated with lenvatinib plus pembrolizumab or treatment of physician's choice. *Eur J Cancer*. 2023;186:172–184. <https://doi.org/10.1016/j.ejca.2023.03.015>